NORTH CAROLINA/SOUTH CAROLINA OTOLARYNGOLOGY AND HEAD & NECK SURGERY

2016 ASSEMBLY

SUNDAY HANDOUTS

JULY 29-31, 2016 BELMOND CHARLESTON PLACE - CHARLESTON, SC

This continuing medical education activity is jointly provided by the North Carolina Society of Otolaryngology and Head & Neck Surgery and Southern Regional Area Health Education Center.



Wake Forest®
School of Medicine

Radiographic Findings of Healing Mandible Fractures

Brent Geffen, Victoria Bones & Jordan L Wallin

2016 NC/SC Otolaryngology Assembly,
July 31, 2016

Disclosures

- I have no relevant financial relationships with the manufacturers of any commercial products and/or providers of commercial services discussed in this CME activity.

8/1/2013

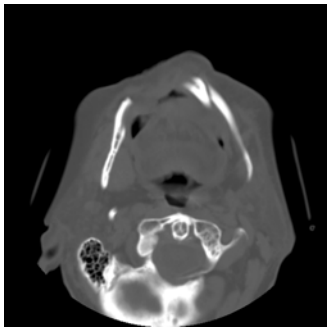

- 82 year old female s/p fall from standing
- Significant PMH: HTN, CHF, DM, COPD, tobacco use
- Original CT 8/1/2013
- Underwent ORIF 8/9/2013

2/18/2014

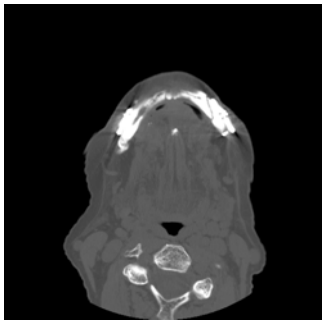

- Persistent post-operative pain
- Screws and plates with concern for hardware loosening
- Non union of fracture line after 6+ months on repeat CT scan
- Returned to OR 3/14/14 for hardware removal, fracture line debridement, bone graft
- Intraoperative note describes stable bony union

Stages of fracture healing

- Long bones heal by endochondral ossification
- Flat bones, including mandible, heal by intramembranous ossification

Fracture assessment

- Strength Challenge
- Histology
- Radiology
  - Plain film
    - Panorex
  - Non-contrast CT

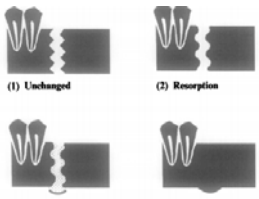

Quantitative Assessment of Experimental Fracture Repair by Peripheral Computed Tomography

P. Augat,[1] J. Merk,[1] H. K. Genant,[2] L. Claes[1]

[1]Department Orthopedics Research and Biomechanics, University of Ulm, Ulm, Germany
[2]Department of Radiology, Osteoporosis Research Group, University of California, San Francisco, 533 Parnassus Avenue, San Francisco, California 94143

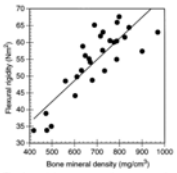

Fig. 4. BMD in a transverse CT-scan at the line of the former osteotomy was strongly correlated to the flexural rigidity of the healed tibia ($R^2 = 0.70$, $P < 0.001$, CV = 10%).

- Tibia osteotomies in sheep
- 9 week healing time
- CT measurements: cross sectional area, projected callus area, bone mineral density
- Correlation with flexural rigidity

A Timetable for the Radiologic Features of Fracture Healing in Young Children

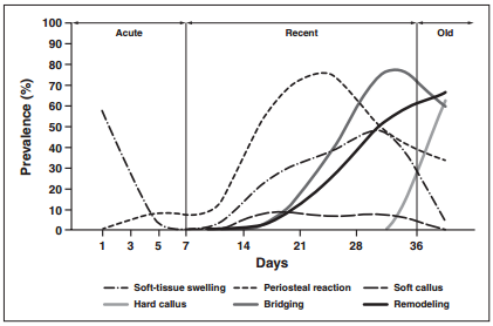

Radiographic changes during bone healing after mandibular fractures

T. Kawai, S. Murakami, H. Hiranuma, M. Sakuda*

*Department of Oral and Maxillofacial Radiology and *Department of Oral and Maxillofacial Surgery, Osaka University Faculty of Dentistry, Osaka, Japan*



Unanswered questions

- What is the expected timeline for healing of mandible fractures?
- If healing has not occurred within the expected time window, is operative exploration warranted?
- What imaging modality is ideal for decision management?
  - Majority of research in literature is based off of long bone healing
  - Few studies on flat bones, none on mandibles

Timeline Data

Retrospective Review

Inclusion Criteria:
- CPT 70486
- Diagnosis codes 802.2X
- Mandible Fracture 2012-2014 Treated at WFBMC

Exclusion Criteria:
- Unavailable post-treatment data.

164 patients

Average age: 36
- 76% male
- 64% smokers

Collected information:

MRN, date of fracture, DOB, age at encounter, sex, BMI, smoking status, significant PMH, fracture diagnosis, treatment date, follow-up imaging, patient signs/symptoms, surgical intraoperative report

50 patients with repeat imaging (CT, panorex)

22 with at least one repeat CT
- 79 fractures
- 86 images

Timeline: signs of healing

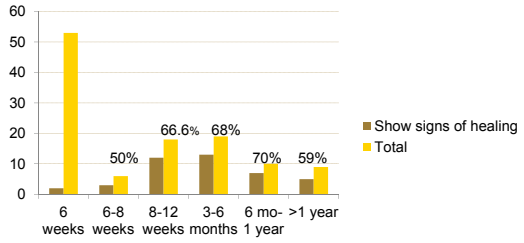

Intraoperative comparisons

- 9 patients with repeat imaging of CT alone (3), panorex alone (1) and both (5) were taken to the operating room for:
  - Non union on radiology report
  - Intractable pain at fracture
  - Signs or symptoms of infection at fracture site

Intraoperative comparisons

- In five of these cases, the intraoperative note described well healed fracture with good bony union and/or immobile fracture,
- Remaining four cases revealed nonunion and/or mobile bony segments intraoperatively, consistent with radiology report

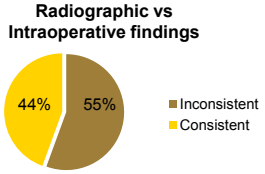

Future directions

- Blinded radiologist reading to identify presence or absence findings associated with healing
  - Each fracture assessed individually by two independent attending radiologists for
    - Blurring of fracture edges
    - Presence of bony callous
    - Cortical continuity
  - Presence or absence will be graded on a 1-5 likert scale, subsequent images will be compared to original CT scan and timing of repeat scan will be blinded

Interobserver agreement

- Prior studies in long bones have documented good interobserver agreement suggesting reproducible results
  - Kappa scores between 0.55 and 0.8 and higher in fractures without splinting or casting

References

- 1. Dijkman, B. G., Sprague, S., Schemitsch, E. H. & Bhandari, M. When is a fracture healed? Radiographic and clinical criteria revisited. J. Orthop. Trauma 24 Suppl 1, S76–80 (2010).
- 2. Kalfas, I. H. Principles of bone healing. Neurosurg. Focus 10, E1 (2001). Protocol version: Template updated 9.24.14 4
- 3. Kawai, T., Murakami, S., Hiranuma, H. & Sakuda, M. Radiographic changes during bone healing after mandibular fractures. Br. J. Oral Maxillofac. Surg. 35, 312–318 (1997).
- 4. Augat, P., Merk, J., Genant, H. K. & Claes, L. Quantitative assessment of experimental fracture repair by peripheral computed tomography. Calcif. Tissue Int. 60, 194–199 (1997).
- 5. Hayward, L. N. M., de Bakker, C. M. J., Gerstenfeld, L. C., Grinstaff, M. W. & Morgan, E. F. Assessment of contrast-enhanced computed tomography for imaging of cartilage during fracture healing. J. Orthop. Res. Off. Publ. Orthop. Res. Soc. 31, 567–573 (2013).
- 6. Lekven, N., Neppelberg, E. & Tornes, K. Long-term follow-up of mandibular condylar fractures in children. J. Oral Maxillofac. Surg. Off. J. Am. Assoc. Oral Maxillofac. Surg. 69, 2853–2859 (2011).

Thank you

Victoria Bones
Jordan L Wallin
Wake Forest Baptist Medical Center
NC & SC Societies of Otolaryngology and Head & Neck Surgery

MUSC Health
MEDICAL UNIVERSITY of SOUTH CAROLINA

The Hemangioma Treatment Foundation
Kids' birthmarks. We care. We cure.

Modern management of nasal hemangiomas—a single surgeon's experience and systematic review of the literature

Robert Keller MD
Marcelo Hochman MD

SC-NC Conference ~ July 2016

Historical Perspective and Current classification scheme

- History plagued by confusing nomenclature, misdiagnosis, and lack of a unified consensus on classification
- 1982 - Mullicken and Glowacki - classification system of vascular anomalies. → distinguished vascular tumors from vascular malformations
- International Society for the Study of Vascular Anomalies (ISSVA)

Hemangiomas	Malformations
Endothelial cell proliferation	Normal endothelial cell cycle
40% present at birth	90% recognized at birth
Rapid postnatal growth and slow involution	Grow commensurately with child



Nasal Hemangiomas

- Infantile hemangiomas of the nose (IHN) comprise a special subset of these tumors due to their impact on a structure with known functional, aesthetic and psycho-social import.
- A more aggressive approach for a wider range of tumors is gaining strength given the excellent efficacy and safety profile of beta blockers, and the availability of an FDA approved formulation for infants with IHs
- The paucity of outcomes data for IHN management, however, makes generalized treatment planning difficult.
- We hypothesized that a standardized therapeutic protocol for IHNs capable of achieving acceptable aesthetic and functional outcomes by 2.5-3 years of age (when a sense of 'self' begins to form) could be developed from consensus literature reports and personal experience

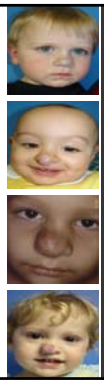

Methods

- OBJECTIVE: to review the senior author's treatment approach for IHNs and to compare with general approach found in the literature
- Retrospectively reviewed patients with IHNs undergoing treatment by the senior author (MH) from 1999-2015
- Patients underwent single and multi-modality treatment with pulsed-dye laser, oral steroids, intra-lesional (IL) steroids, oral propranolol, and surgery.
- All with a minimum 1 year follow-up
- Post-operative surgeon and parent satisfaction with surgical outcome was assessed
- We additionally performed a systematic review of the literature following *Reporting Items for Systematic reviews and Meta-Analyses (PRISMA)* guidelines

Results: *demographics*

- A total of 86 patients underwent treatment for IHNs and were included in the study
- Mean age of the study population at presentation was 4.8 months (range 2 days - 23 years).
- There were 64 females and 22 males treated.
- Mean follow-up was 3.5 years (range 12-180 months).
- There were 12 (14%) superficial, 13 (15%) deep, 59 (63%) compound, and 2 (2%) complicated IHNs at presentation.

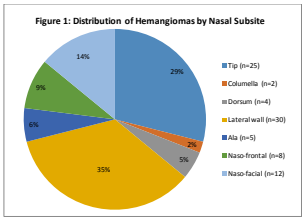

Results: *treatment modalities*

Modality	Dose	Frequency	Duration	Comments
Observation	n/a	n/a	Arbitrary length of time until intervention is deemed necessary	n/a
Pulsed-Dye Laser (PDL)	7-10mm spot size 7-9 j/cm2 1.5-6msec duration DCD 30:20	monthly for superficial components, every 10 days for ulceration	3-8 treatments for superficial lesions, 2-4 treatments for ulcerated lesions	n/a
Systemic Corticosteroids	3-5mg/kg/day	daily	based on response during proliferation only	(prior to 2008)
Intralesional Corticosteroids	triamcinolone 20 – 40 mg/ml	based on response	based on response	(prior to 2008)
Propranolol	2mg/kg/day	BID	Proliferation through early involution	until acceptable result or change in modality

Results: *treatment based on tumor life cycle at presentation and hemangioma subtype*

Life Cycle Phase	N (%)	Treatments considered
Proliferation	46 (53)	
early (<3m)	27 (31)	observation propranolol PDL corticosteroids (prior to 2008)
late (>3m up to 6m)	18 (21)	observation propranolol PDL corticosteroids (prior to 2008)
Plateau (>6 up to 9m)	9 (10)	observation PDL surgery
Involution	31 (36)	
early (<9m up to 24m)	24 (28)	observation PDL surgery
late (>24m)	7 (8)	PDL surgery

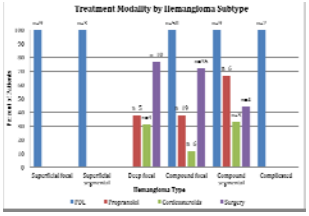

Results: *Treatment of IHNs with Propranolol, Pulsed-Dye Laser or Both Modalities*

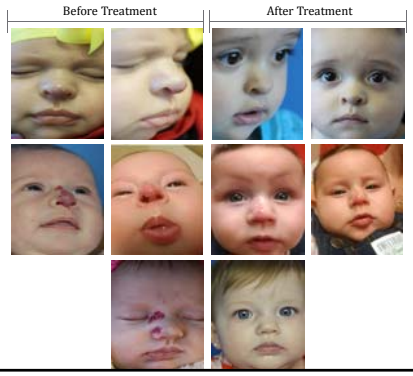

Results: *surgical management of IHNs*

Results: *systematic review*

Reference	Level of Evidence, Relation to propranolol discovery	Patients (N)	Mean Follow up (range), months	Modality - N (%)	Outcome Measure	Comments / Conclusions
Ben-Amitai et al 2013	Level IV post-propranolol	10	14-16m or until end of proliferative period	Propranolol 10 (100)	Visual grading	Early treatment of IHNs with propranolol prevents lesion proliferation, reduces lesion volume, and prevents nasal and facial deformation.
Eivazi et al 2010	Level IV pre/post-propranolol	23	35 (9-120)	Surgery - 6 (26) Nd:YAG - 6 (26) Observed - 6 (26) Cryotherapy - 3 (13) Propranolol - 2 (9)	Blinded photo Evaluation of responses before and after	Limited lesions do not require therapy. The results with Propranolol are encouraging. Laser and cryo-therapy have to be critically reevaluated. Treatment of choice for lesions that are not suitable for beta blockers and residual disease is surgery.
Arneja et al 2010	Level IV pre-propranolol	25	45.3 (16-108)	1) Steroid - 18 (syst (3) or intralesional (15)) – proliferation 2) PDL LASER -20 – following steroid in proliferation / plateau. 3) Surgery -15 - in post-involution period if indicated (11) or in plateau after PDL (4).	Parent subjective report of aesthetic satisfaction	Combined medical and surgical approach offers the best method to treat the IHNs. Early medical management used to accelerate involution of the lesion, optimizing conditions for subsequent surgery. Early surgery via open rhinoplasty approach with skin resection allows for satisfactory results– may need secondary correction.
Simic et al 2009	Level IV pre-propranolol	14	Range 14-72 months	Single modality or Combination 1) Intralesional steroid - 5 (36) 2) surgical excision - 9 (64) - lenticular incision (2), circular incision (2), open rhinotomy (5)	Visual subjective grading scale completed by 3 doctors and parents:	IL steroids should be the first line of treatment during the proliferative phase. Early surgery performed at the end of the proliferation or during second year of life is perferred to avoid functional and psychosocial issues.
Faguer et al 2002	Level IV pre-propranolol	6	25 (6-67)	Surgery during involution period: Rethi incision and double rim incision. Do not advocate skin excision (spontaneous retraction)	preop/postop subjective appearanceas graded by parents, surgeons, dermatologists, students, ancillary staff.	Surgery around 2 years of age which involves Rethi incision and double rim incision without skin excision is optimal treatment given functional and cosmetic disability associated with IHNs. Incisions are 'nearly invisible' and surgery is effective for large IHNs.
McCarthy et al 2001	Level IV pre-propranolol	42	69 (10-44)	Observation 20 (48) Surgery 22 (52) via open rhinoplasty	Parent subjective assessment Serial photographs taken post-operatively, reviewed for outcome by surgeon	Open rhinoplasty technique allows for avoidance of unsightly scars on the nose and long-term outcomes are good, however, future cartilage grafting, and laser treatment to lighten the residual superficial component may be necessary.

Reference	Level of Evidence, Relation to propranolol discovery	Patients (N)	Mean Follow up (range), months	Modality - N (%)	Outcome Measure	Comments / Conclusions
Hamou et al 2009	Level IV pre-propranolol	39	48	Early Surgery Low volume – mean 1 surgery High volume – mean 1.9 surgeries Performed Rethi, double rim, or midline lenticular incisions.	3 pre-op and 3 post-op photos graded by blinded dermatologist, surgeon, parents	Early surgical treatment for IHNs must be individualized according to degree of cutaneous infiltration, the presence of a misalignment of the cartilages and the severity of nasal volume increase. Double rim, rethi, nasal midline and paranasal vertical approaches are all options.
Waner et al 2008	Level IV pre-propranolol	44	41.6	external rhinoplasty: 13 (30) elliptical midline incision: 2 (4) modified subunit incision: 29 (66)	2 independent investigators assessing post-operative outcome by photo review; also considered satisfaction of the patients or parents	Modified subunit surgical technique shows superior results to former techniques; early surgical intervention is preferred
Perkins et al 2014	Level III pre/post-propranolol	58	>6 months minimum, mean not specified	Laser- 29 Surgery- 16 Steroids- 20 Propranolol- 25	Grading system: 4 grades based on depth, nasal subunit involvement and functional impairment; assesed grade change after treatment by 2 reviewers	Patients with isolated propranolol-treated IHN were less likely to undergo invasive treatment, but despite its implementation, the need for invasive treatment was not totally supplanted by its use.'
Hochman et al 2016	Level III/IV pre/post-propranolol	86	42 (12-156)	PDL 73 (85) Propranolol 30 (35) IL Steroids 2 (2) Systemic steroids 11 (13) Surgery 50 (58) Note: multi-modality- many pts	Parent subjective report of aesthetic satisfaction Surgeon subjective report of satisfaction	Treating physicians should practice a multimodality approach tailored to IHN subtype and phase of tumor life cycle, including active observation versus early medical therapy (propranolol or PDL), followed by surgery or PDL in the early post-proliferation phases to optimize cosmetic/functional outcomes by age 2-3

Concl
manage algorith

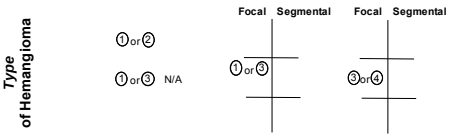

Conclusions:

- Although higher levels of evidence supporting optimal treatment algorithms for IHNs remain absent, the best available evidence supports a general consensus advocating for multi-modality approaches to treatment.
- Specifically, initiation of medical therapy early during the proliferation phase, alone or with concomitant pulsed-dye laser therapy, followed by more invasive options if necessary once proliferation has ceased, is generally supported.
- An individualized approach that primarily considers IHN type, phase of tumor life cycle at presentation, developmental and social milestones, and parent preferences is reflected in the literature and our experience.
- Prospective randomized controlled trials of newer medical agents (mTOR inhibitors, topical beta blockers), technologies and techniques remain necessary

Evaluation of Nerve Integrity in Children with Auditory Neuropathy Spectrum Disorder using Electrocochleography

Christopher Giardina
GS3, MD/PhD Program
Fitzpatrick Laboratory
UNC School of Medicine

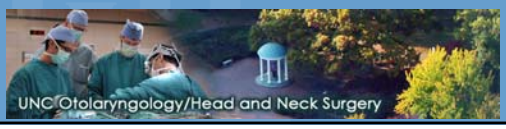

Acknowledgements

- CI Surgeons:
  - Dr. Oliver Adunka
  - Dr. Kevin Brown
  - Dr. Craig Buchman
  - Dr. Harold Pillsbury
- Audiologists:
  - Dr. Meredith Anderson
  - Dr. Meg Dillon
  - Dr. Lisa Park
  - Dr. Holly Teagle
- Scientists:
  - Dr. Doug Fitzpatrick
  - Dr. Paul Manis
- Residents and Medical Students:
  - Zach Bastian
  - Dr. Tatyana Fontenot
  - Dr. Eric Formeister
  - Andrew Pappa
  - Dr. Joseph Roche
  - William Scott

Disclosures

- None

ANSD

- Auditory neuropathy spectrum disorder (ANSD) is a hearing disorder characterized by normal cochlear function but a loss of information transmission to or within the auditory nerve.
- Children with ANSD represent an increasingly large fraction of cochlear implant (CI) recipients as the condition becomes better recognized and identified.
- There exists a need to better identify and characterize the cochlear physiology of children with ANSD.

Objective

- To compare the cochlear physiology of children with ANSD to that of other children receiving cochlear implants

Approach: Electrocochleography

- With auditory stimuli it is possible to assess the hair cell and neural contributions through inspection of a compound action potential (CAP), the cochlear microphonic and auditory nerve neurophonic (CM/ANN), and the summating potential (SP).

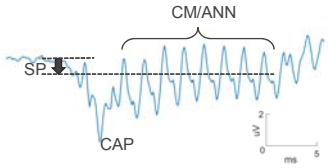

Rationale

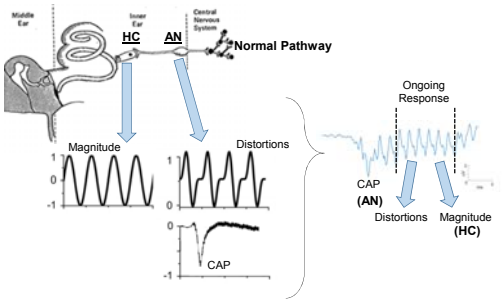

Hypotheses

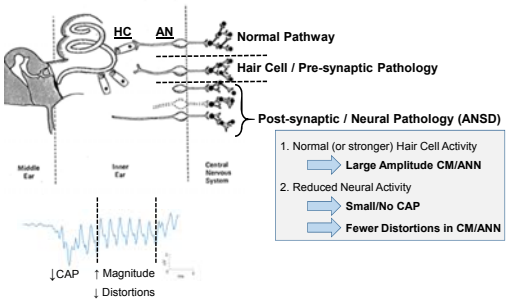

Methods

- Identification of Children with ANSD
  - Wave 1 on ABR with a severely diminished or absent Wave 5
- Measures at the RW just before CI insertion
  - Intraoperatively, stimuli consisted of a frequency series of tone bursts 0.25-4 kHz at 90 dB nHL).

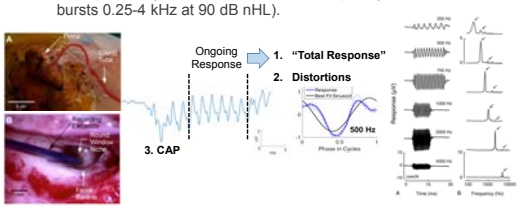

Measure 1: Magnitude of Ongoing Response

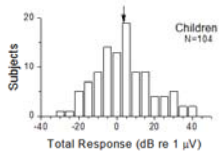

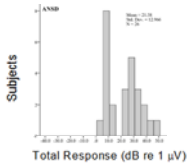

Ongoing Response Strength by Etiology

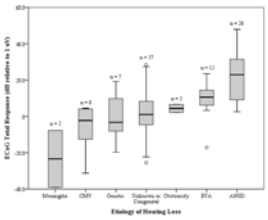

Measures 2 and 3: CAP and ANN Distortions → Nerve Score

- CAP given a score (0 – 2)
  - 0 = No CAP to any stimulus frequency
  - 1 = Small CAP to one frequency
  - 2 = Strong CAP to multiple frequencies

Nerve Response to High Frequencies

- ANN distortions in ongoing response given a score (0 – 2)
  - 0 = No distortions at any stimulus frequency
  - 1 = Some distortions at one frequency
  - 2 = Significant distortions at multiple frequencies

Nerve Response to Low Frequencies

- Scored by 3 different people, blinded to etiology

Nerve Score of 4

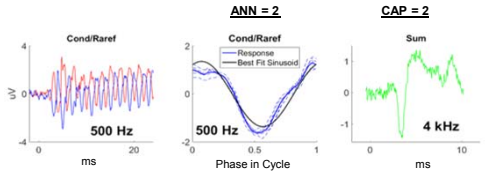

Nerve Score of 3

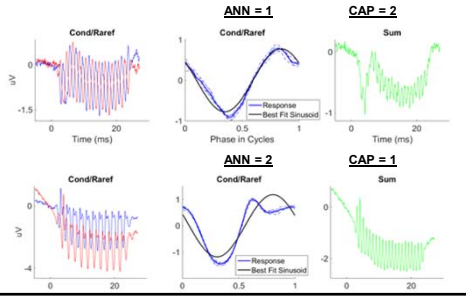

Nerve Score of 2

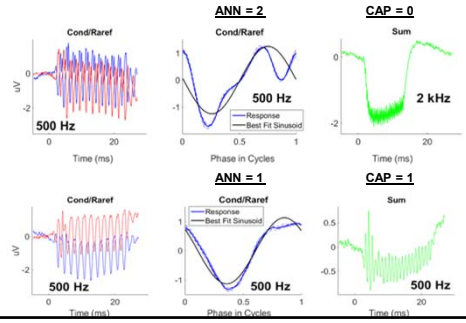

Nerve Score of 1

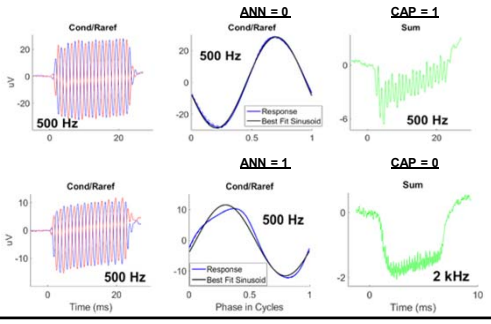

Nerve Score of 0

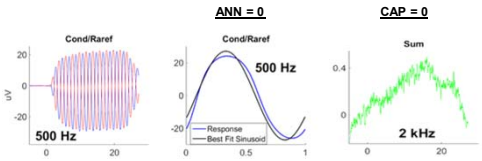

Nerve Score and Etiology

ANSD subjects have less evidence of neural activity

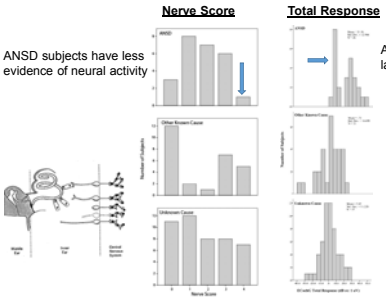

ANSD subjects have larger ongoing responses

Conclusions

- Round window ECochG provides unique information about cochlear physiology in pediatric ANSD subjects that is not available using scalp electrodes.
- ANSD subjects have response magnitudes that are higher and nerve scores that are lower than other pediatric subjects.
- Cases with ANSD show distinctive patterns of response, including the presence or absence of a CAP and ANN, that may be indicative of the site of pathology and ultimate performance with an implant.

Acknowledgements

- CI Surgeons:
  - Dr. Oliver Adunka
  - Dr. Kevin Brown
  - Dr. Craig Buchman
  - Dr. Harold Pillsbury
- Audiologists:
  - Dr. Meredith Anderson
  - Dr. Meg Dillon
  - Dr. Lisa Park
  - Dr. Holly Teagle
- Scientists:
  - Dr. Doug Fitzpatrick
  - Dr. Paul Manis
- Residents and Medical Students:
  - Zach Bastian
  - Dr. Tatyana Fontenot
  - Dr. Eric Formeister
  - Andrew Pappa
  - Dr. Joseph Roche
  - William Scott

Nerve Contributions

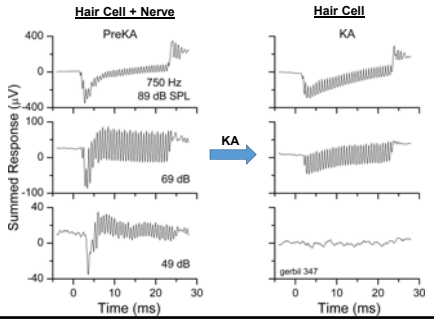

GRU
GEORGIA REGENTS UNIVERSITY
AUGUSTA

Nuances in Parathyroid Disease Evaluation and Management

David J. Terris, M.D.

Department of Otolaryngology / Head & Neck Surgery

Disclosures

- Director of thyroid courses (Genzyme)

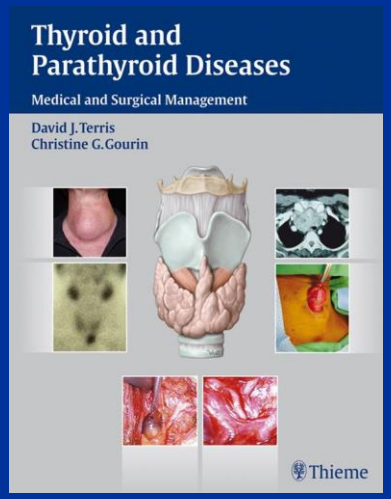







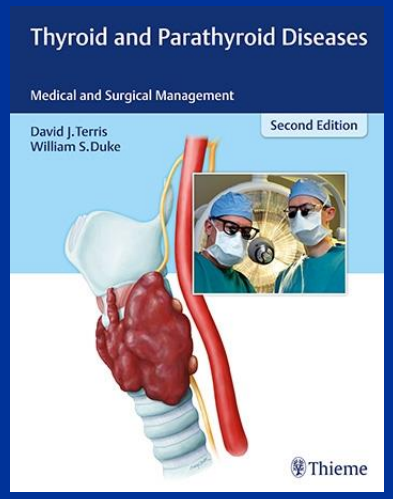

2009 2012 2013 2014 2016

Most changed operation

- Large incision
- Drains
- Inpatient hospitalization
- Complications common



Recent Advances

- IOPTH
- Image-guidance
- High-resolution endoscopy

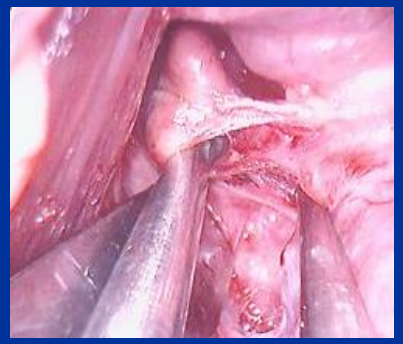

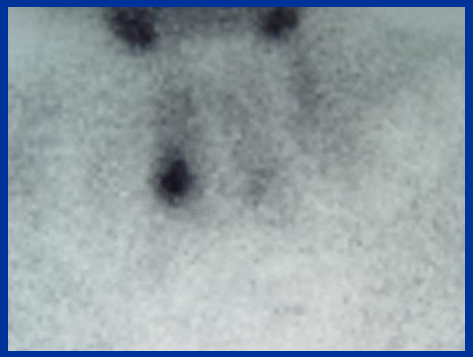

- Minimally invasive, outpatient surgery

GRU
GEORGIA REGENTS UNIVERSITY
AUGUSTA

5 Parathyroid traps . . .

. . . and how to avoid them

- "normal" PTH level in setting of hypercalcemia
- Non-simultaneous PTH and calcium levels
- 24-hour urine calcium
- Negative imaging and the "missing adenoma"
- Persistent eucalcemic hyperparathyroidism after successful parathyroid surgery

Primary Hyperparathyroidism

- Confirm the diagnosis
- Decision for surgery
- Localization
- Choose surgical technique

Confirm the Diagnosis

- In presence of hypercalcemia, PTH should be zero (or close to it)
- If PTH is not low, at least one of the 4 glands is “non-suppressed”
- The “normal” PTH level is not normal relative to the calcium

Confirm the Diagnosis

- PTH changes minute to minute
- A finding of hypercalcemia, then several days later acquisition of a PTH level
- Simultaneous levels should be obtained

Urine calcium assessment

- Urine calcium is an absolute value
- If collection is incomplete, the number will be falsely low
- Total urine volume <1000 to 1500 cc is a clue

Beware of 2-d imaging

- Overly descended superior adenoma is most common reoperative surgery
- Etiology – planar imaging reveals “lower pole adenoma”, presumed to be inferior gland

Planar imaging

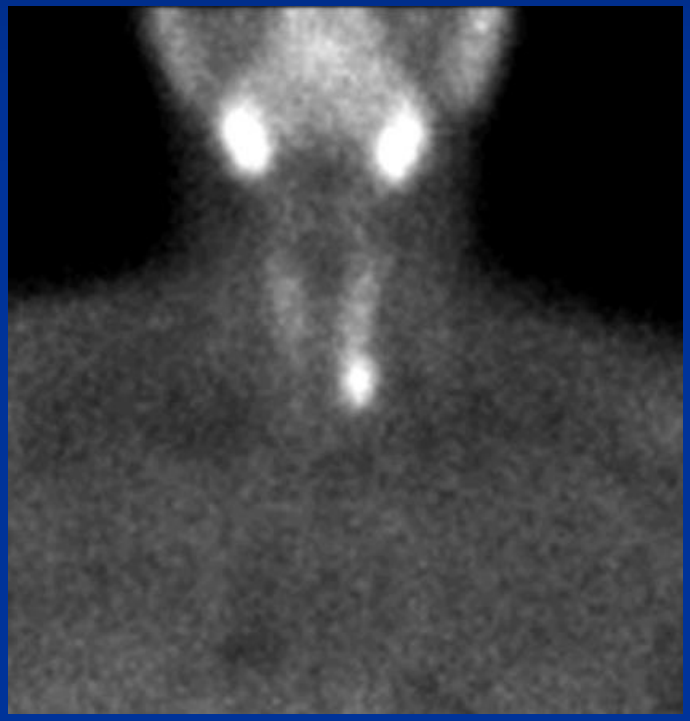

15 minutes

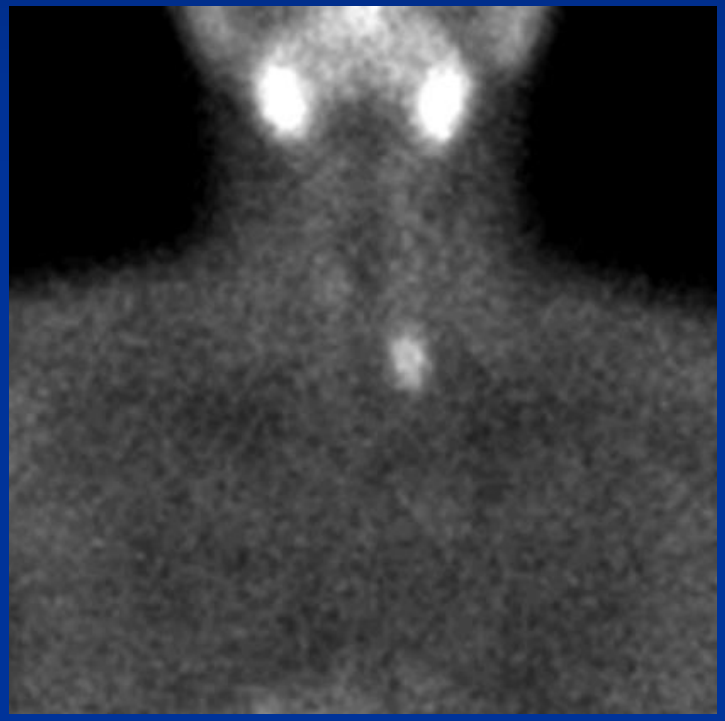

2 hours

Beware of 2-d imaging

- Overly descended superior adenoma is most common reoperative surgery
- Etiology – planar imaging reveals “lower pole adenoma”, presumed to be inferior gland
- Dissection insufficiently deep; paraesophageal

CT-Mibi

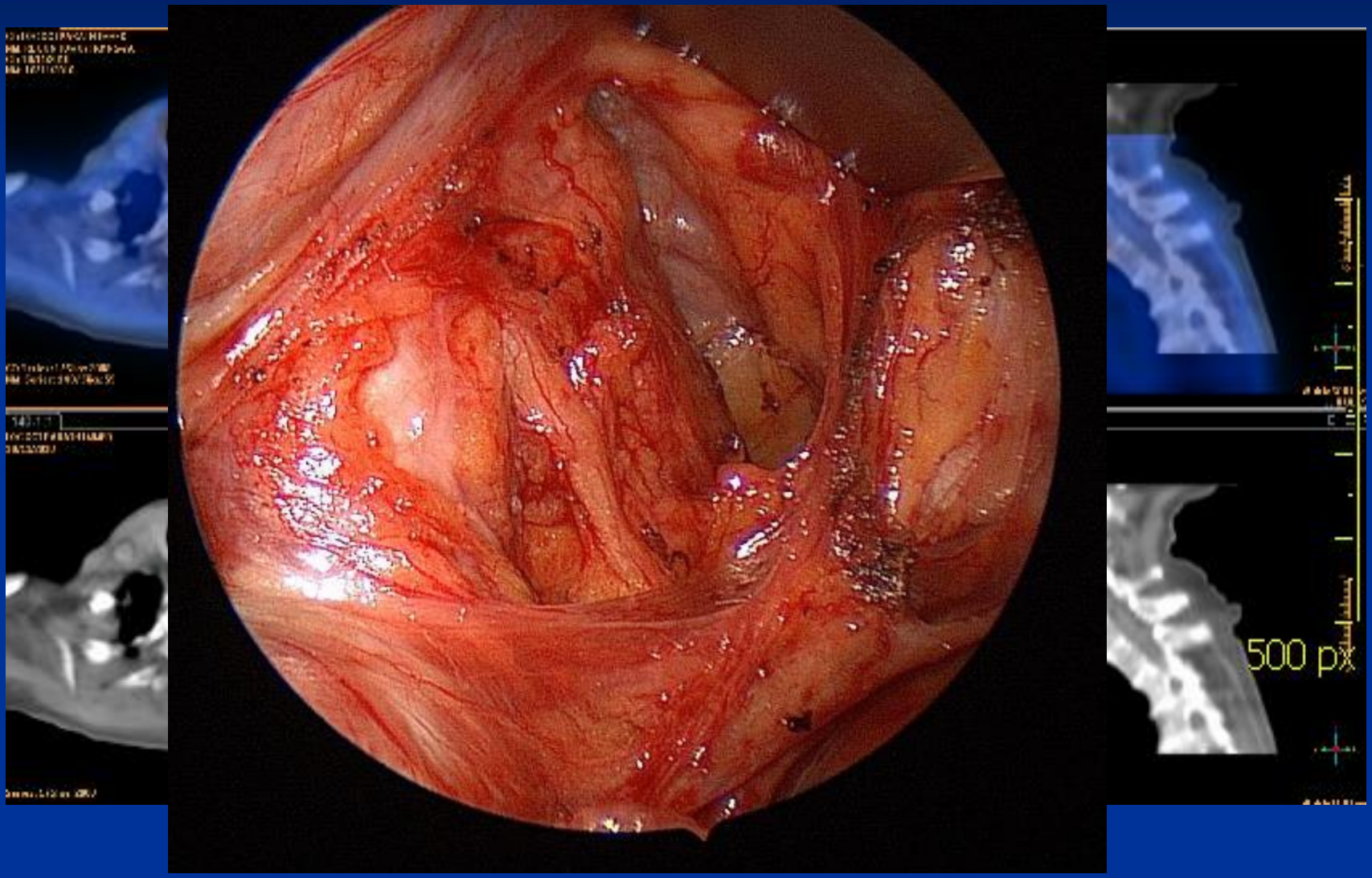

Overly-descended superior

- If inferior gland looks normal do not remove it
- Dissect dorsal to the RLN, expose the esophagus

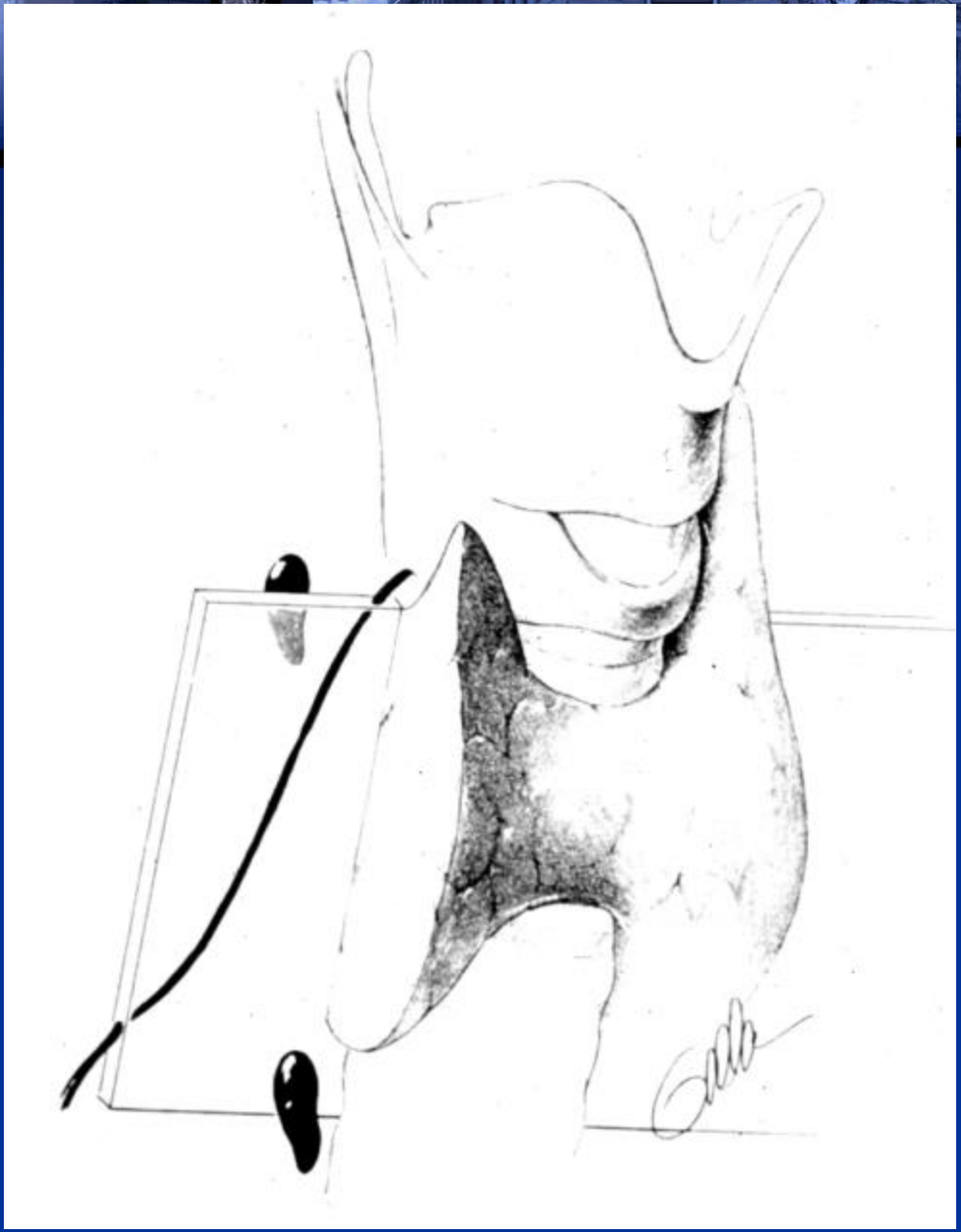

Randolph et al, *Surgery of the Thyroid*

Overly-descended superior

- If inferior gland looks normal do not remove it

Original Research

Reoperative Parathyroidectomy: Overly Descended Superior Adenoma

William S. Duke, MD[1], Hampton M. Vernon[1], and David J. Terris, MD[1]

Limitations of Sestamibi

False Positives

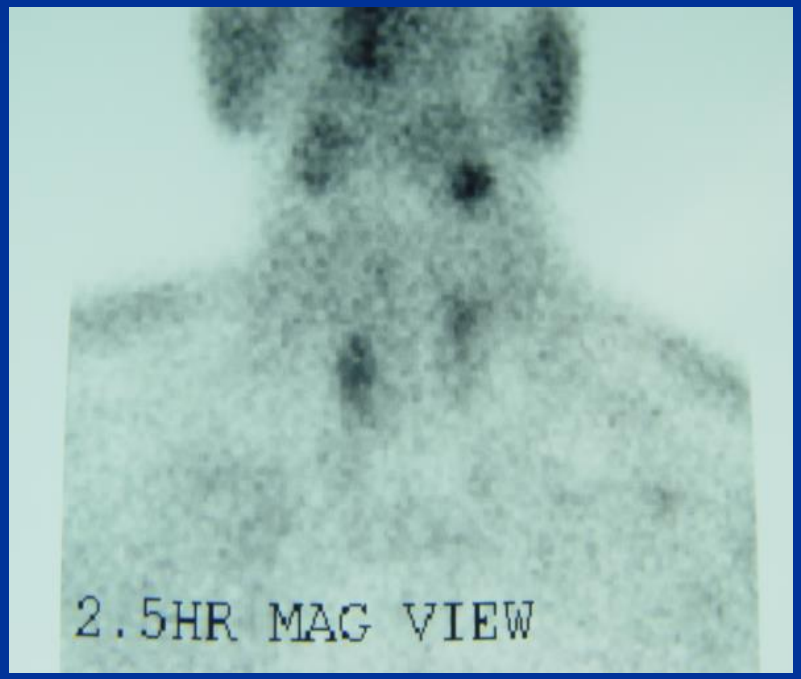

Interpreting reports

- If the US report says "normal thyroid" except for "posterior hypoechoic thyroid nodule"

That's the parathyroid adenoma

- If the US report says "normal thyroid" except for "posterior hypoechoic thyroid nodule", and then an FNA is done showing follicular cells, favor follicular neoplasm

That's STILL the parathyroid adenoma

Surgeon-performed ultrasound

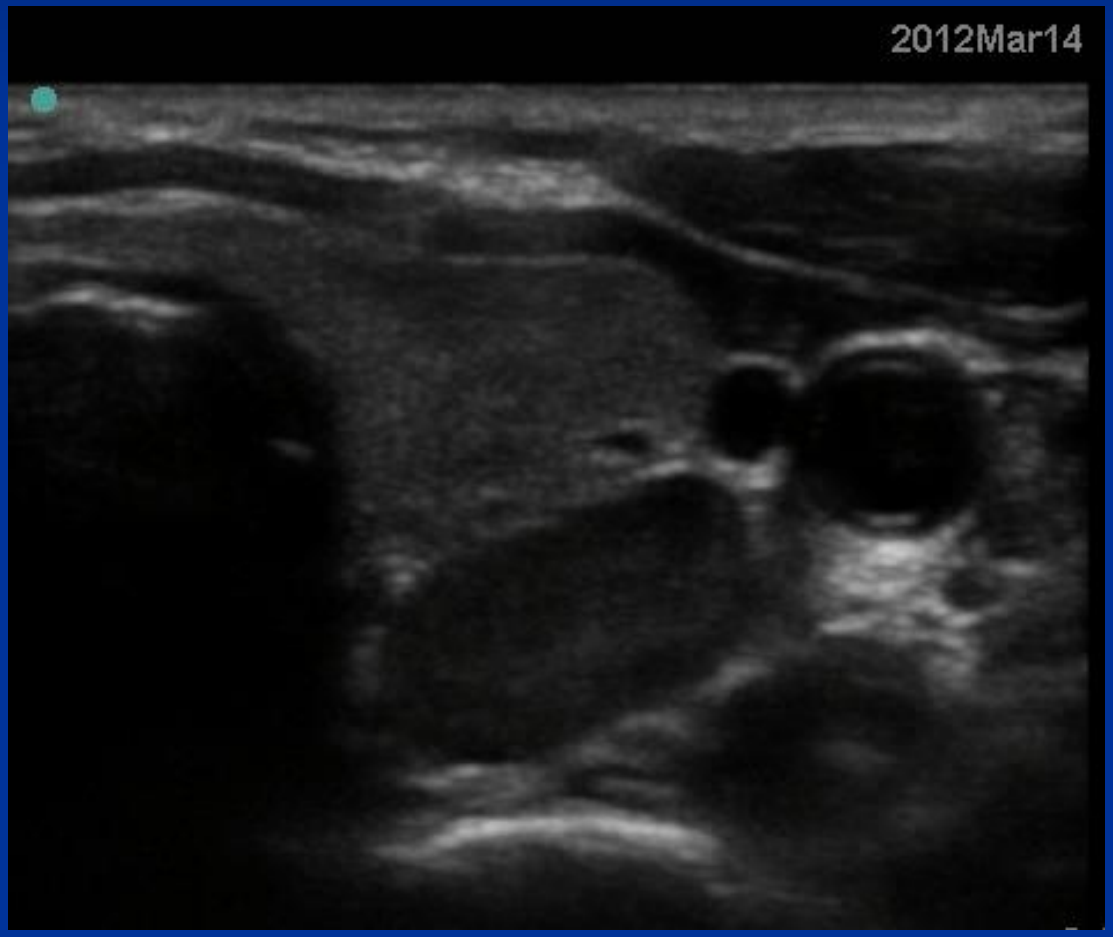

Ultrasound pearls

- Turn the probe to demonstrate orientation of the adenoma (distinguish from lymph node)

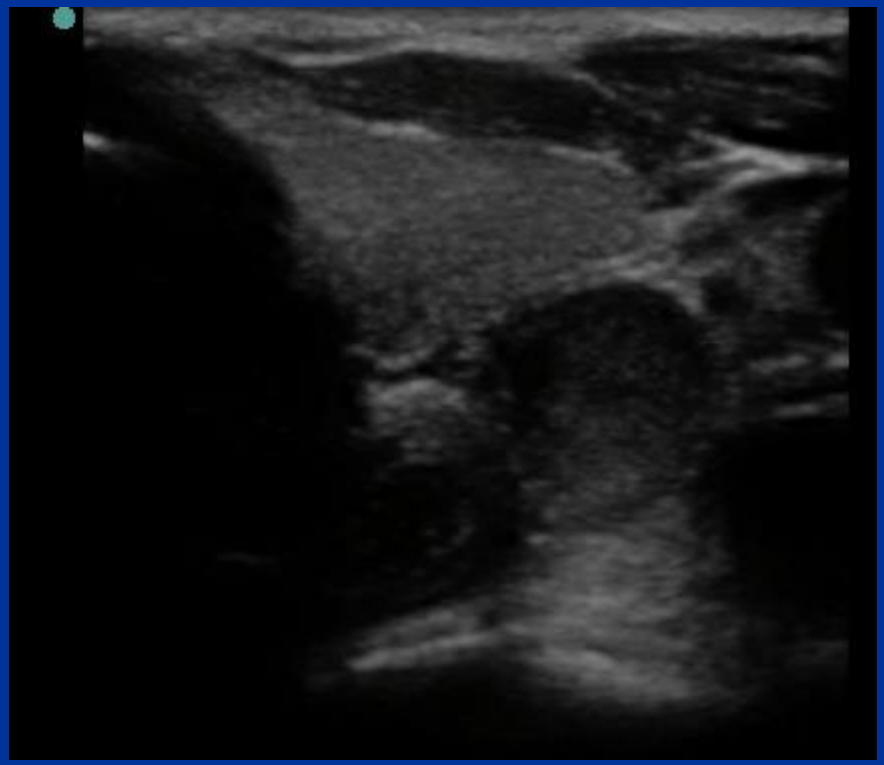

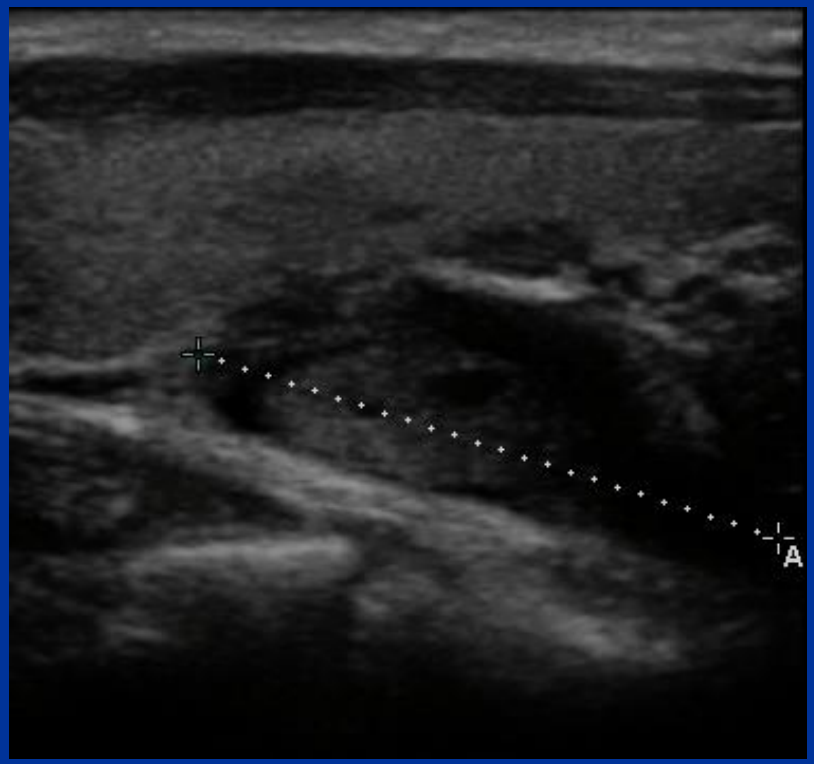

Ultrasound pearls

- Turn the probe to demonstrate orientation of the adenoma (distinguish from lymph node)
- Explore for pedicle with Doppler
- If adenoma not seen on US, suspect deep gland

Ultrasound pearls

- Turn the probe to demonstrate orientation of the adenoma (distinguish from lymph node)
- Explore for pedicle with Doppler
- If adenoma not seen on US, suspect deep gland
- Immediate preop US on the table

Immediate Preop US

Read your own scans

- 63 yo female with PHPT

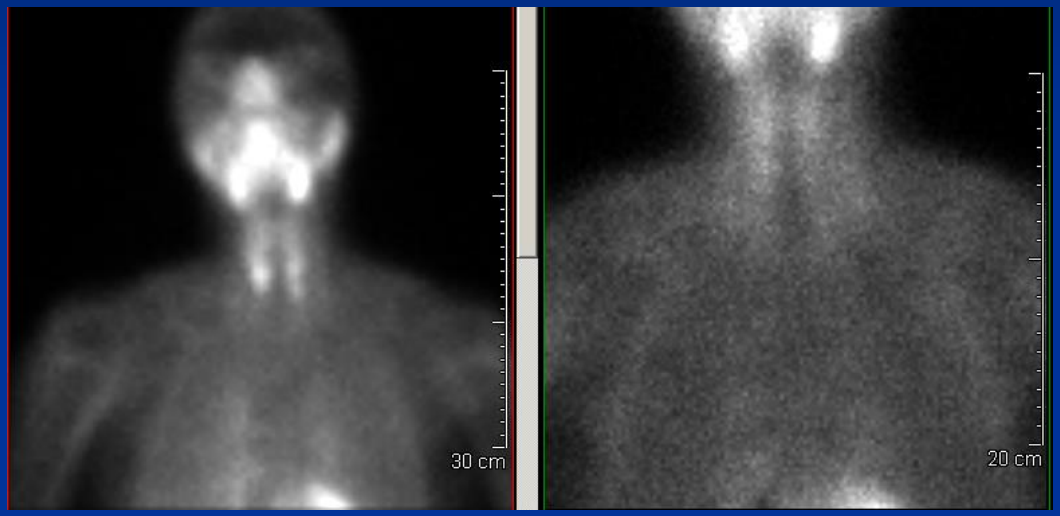

	Time	PTH
Baseline	X	135.9
Excision	0805	X
5	810	35.2
10	815	21.5
15	820	

Read your own scans

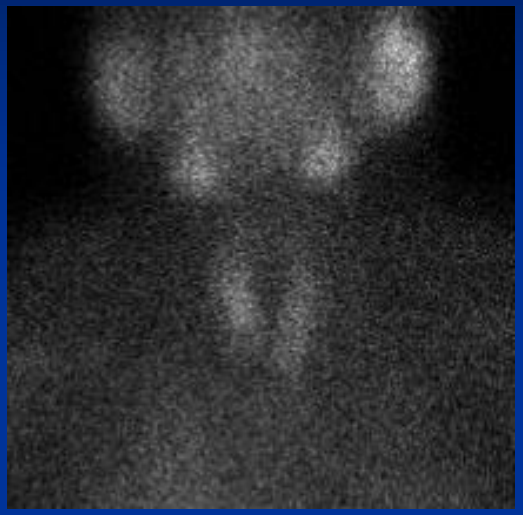

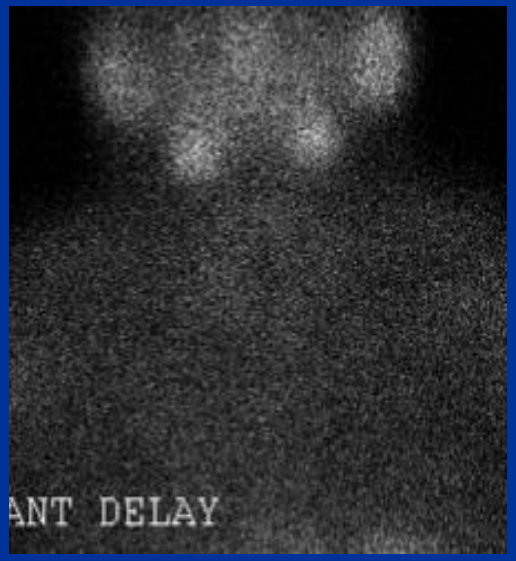

Left Inferior Parathyroid Adenoma

Read your own scans

A novel technique to improve the diagnostic yield of negative sestamibi scans

Sapna Nagar, MD,[a] David D. Walker, MD,[b] Omran Embia, MD,[a] Edwin L. Kaplan, MD,[a] Raymon H. Grogan, MD,[a] *and* Peter Angelos, MD, PhD,[a] *Chicago, IL*

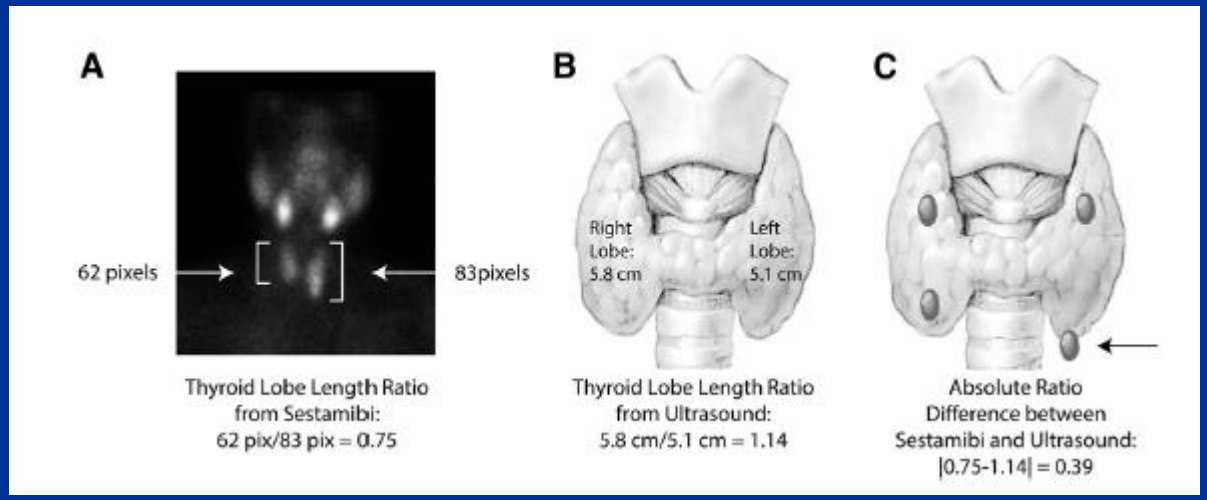

Nagar et al, Surgery, 2014

Sestamibi-negative patients

Improved Localization of Sestamibi Imaging at High-Volume Centers

Michael C. Singer, MD; Darko Pucar, MD, PhD; Manoj Mathew, BS; David J. Terris, MD

Objectives/Hypothesis: Sestamibi imaging can provide critical information regarding the location of suspected parathyroid adenomas. However, this modality can be challenging to perform and interpret reliably. The impact of experience on the localizing efficacy of sestamibi scanning was assessed.

Study Design: Prospective analysis of a consecutive series of patients undergoing parathyroidectomy was undertaken after institutional review board approval was obtained.

Methods: Patients undergoing parathyroid surgery from October 2003 through June 2011 were considered. Inclusion criteria represented primary surgery for primary hyperparathyroidism, in which a single adenoma was excised and cure obtained. Sestamibi scan results, performed at our institution and at outside imaging centers, were compared to intraoperative findings.

Results: There were 389 parathyroidectomies performed; 188 patients met inclusion criteria. Fifty-four patients had sestamibi scans performed at outside institutions; 36 (67%) were localizing and 18 (33%) were nonlocalizing. Among localizing studies, half identified the correct quadrant and half recognized the correct side. At our institution, 147 patients underwent sestamibi imaging; 121 (82%) localized and 26 (18%) did not. Among localizing studies, the correct quadrant was reported in 64% and the correct side in 36%. Of the 147 scans performed at our institution, 13 represented repeat scans of patients with nonlocalizing outside scans. All 13 of these localized; six identified the correct quadrant and seven the side of the adenoma.

Conclusions: A high volume of experience may improve the yield of sestamibi imaging. Repeating this study at a high-volume center when it was nonlocalizing elsewhere may provide useful additional information.

Key Words: Parathyroidectomy, parathyroid, sestamibi, clinical competence, imaging, minimally invasive.

Level of Evidence: 4

Laryngoscope, 000:000–000, 2012

Singer et al, Laryngoscope, 2012

Results

Among 18 outside negative scans

- 5 = read as positive
- 13 = study repeated at GRU
- All 13 patients (100%) localized

Beware of rapid washout

Outside sestamibi negative

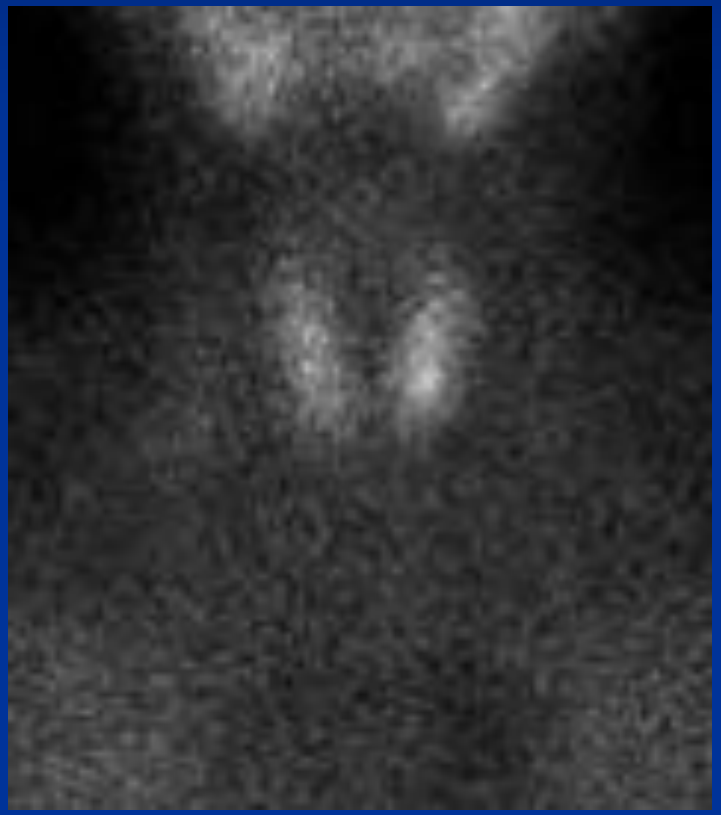

15 min

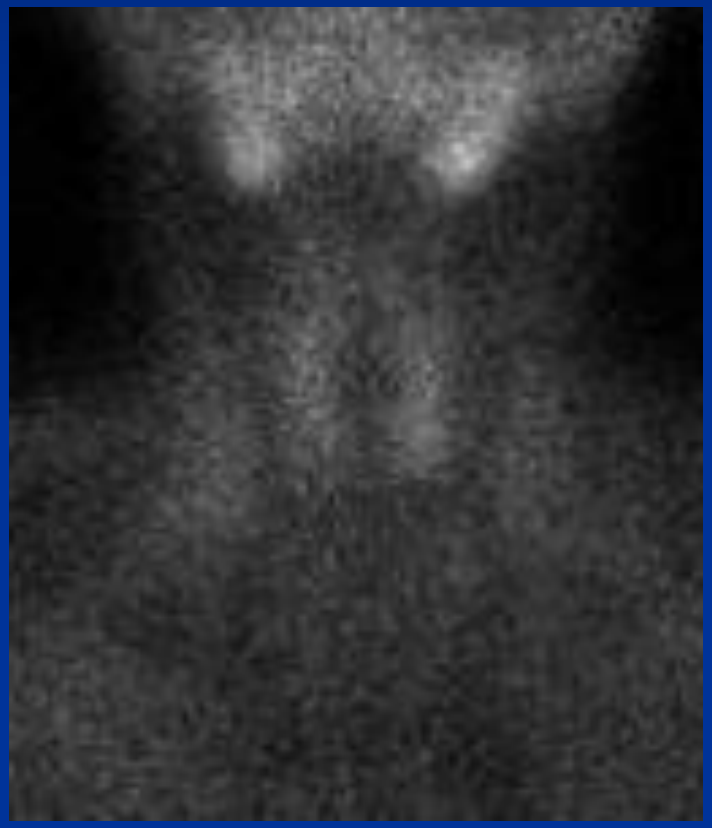

3 hr

Sestamibi repeated at GRU

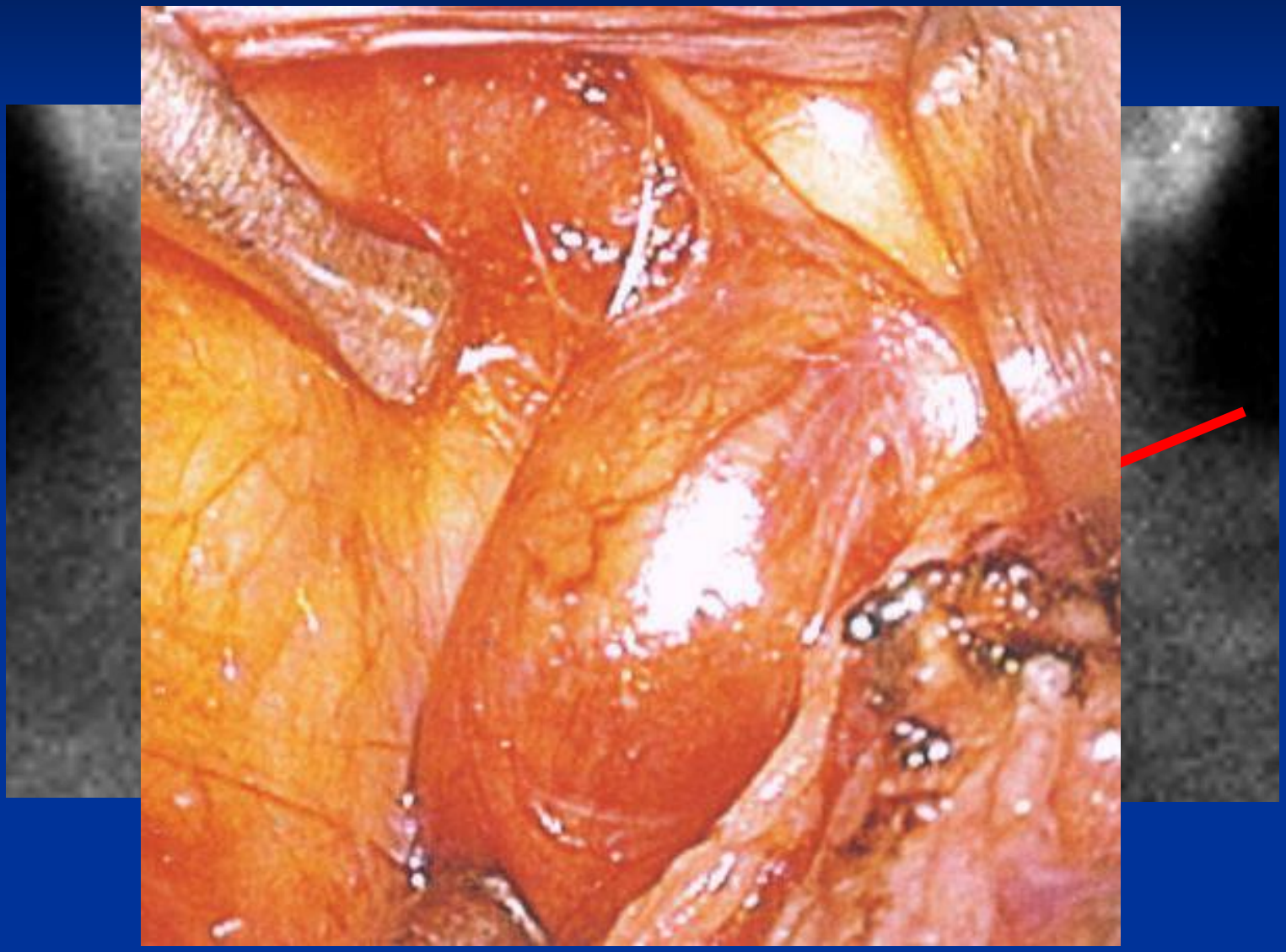

Know your consultants

- If low volume
- If poor quality
- If low-yield for positive studies

Imaging adjuncts

- FNA of suspected adenomas; send the aspirate for PTH level (<10 or >1000)
- Can be done preoperatively (usually only in reoperative setting) or intraoperatively
- Bilateral jugular venous aspiration exploring for differential (preoperatively or intraoperatively)

Principles of Exploration

- Bloodless, magnified dissection
- Low threshold to identify RLN
- Use ballotment to reveal adenoma
- Systematic dissection, using knowledge of anatomy and embryology
- Avoid removing normal parathyroid glands

Intraoperative PTH

- 84 a.a. polypeptide; t½ = 2-5 minutes
- Immunochemiluminescent assay
- Turnaround 8-30 minutes
- “biochemical frozen section”
- Essential when performing a limited parathyroidectomy

“rapid” IOPTH

Future Diagnostics

71 yo female with PHPT

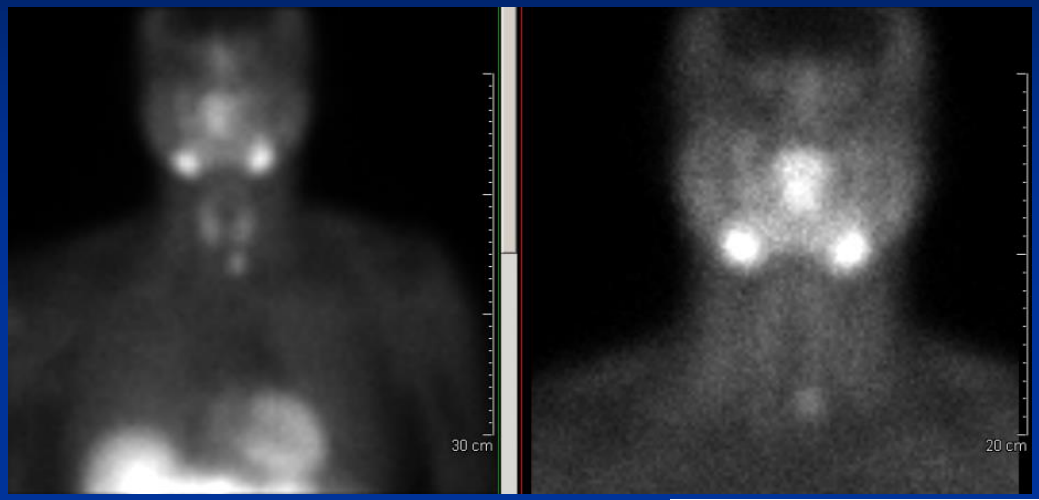

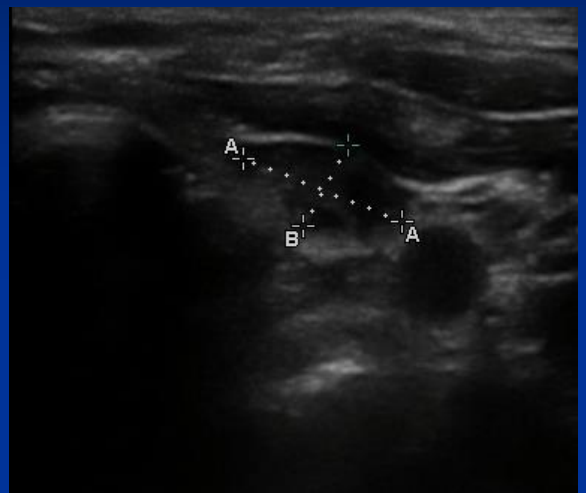

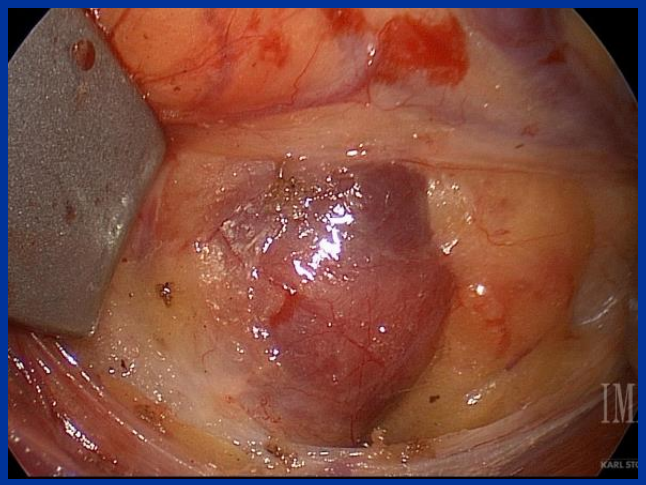

	TIME	PTH
BASELINE	---	189.1
EXCISION	1124	---
5 MIN	1129	42.7
15 MIN	1143	27.4

52 y.o. woman with PHPT

- Ca++ 11.0, PTH 211
- Co-localizing R inferior

456 mg adenoma

	Time	PTH
Baseline	X	194.1
Excision	0839	X
5 min	0844	91.3
10 min	0849	83.2
15 min	0854	87.2
25	09:05	92.8

Continued exploration

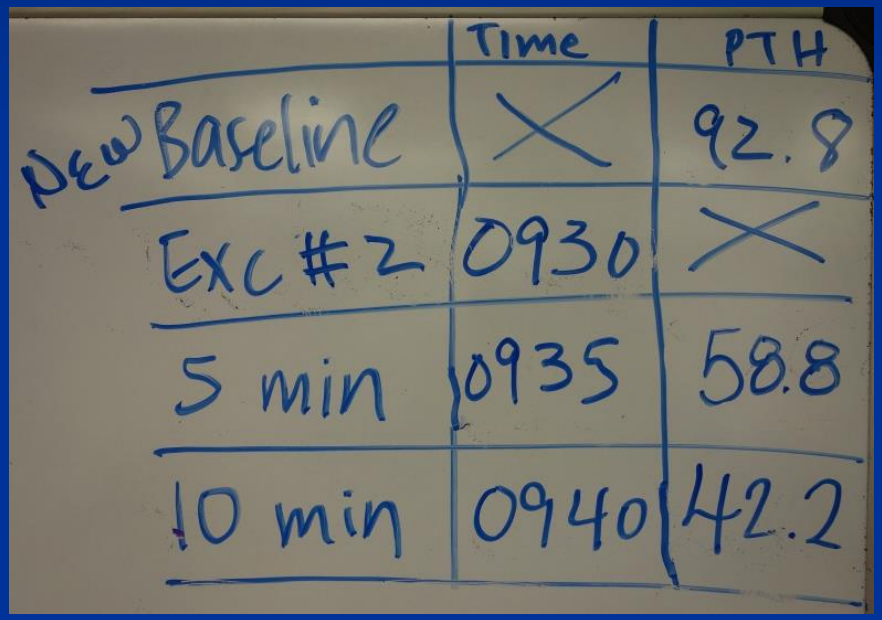

	Time	PTH
New Baseline	X	92.8
Exc #2	0930	X
5 min	0935	58.8
10 min	0940	42.2

312 mg adenoma

Algorithm


Level I
Level II
Level III
Level IV
Surgery start
Pre-incision level
Excision
5-min level
10-min level
15-min level
Surgery termination

MI Parathyroidectomy

Many definitions have been proposed:

- **Local anesthesia**
- **Endoscopic**
- **Mini-incision**
- **Remote access**
- **Radioguided**

MI Parathyroidectomy

Critical elements

- ***Single-gland surgery***
- Image-guided
- Confirmation of cure (PTH)
- Outpatient
- ½ to ¾ inch incision
- Endoscopically-assisted

Endoscopic Parathyroidectomy

- Local or general anesthesia
- 15 to 20-mm incision
- Vertical separation of strap mm.
- Mobilization/retraction of thyroid
- Endoscopic visualization
- Microdissection of adenoma

Endoscopic Parathyroidectomy

Instrumentation

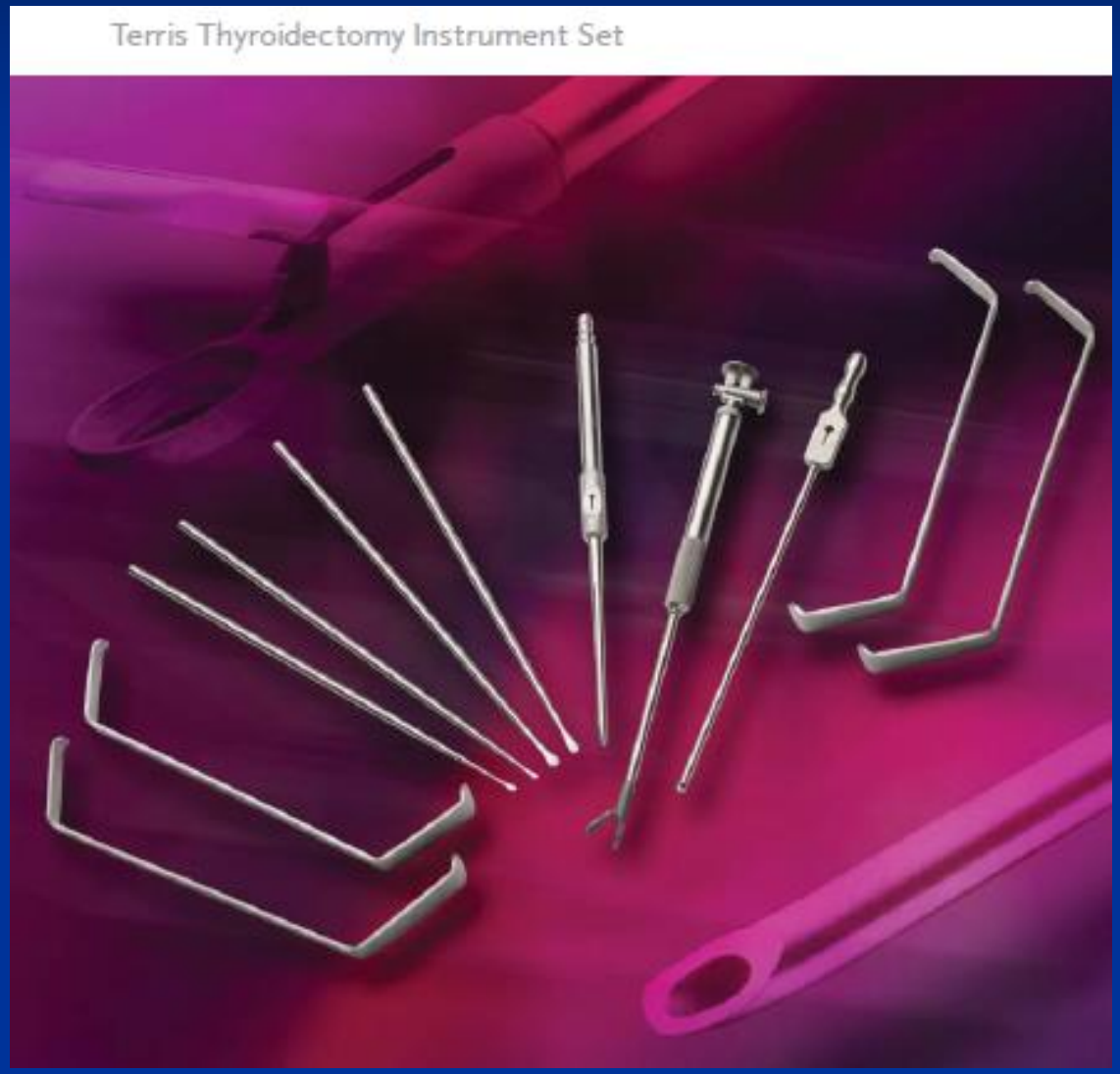

Identification of Adenoma

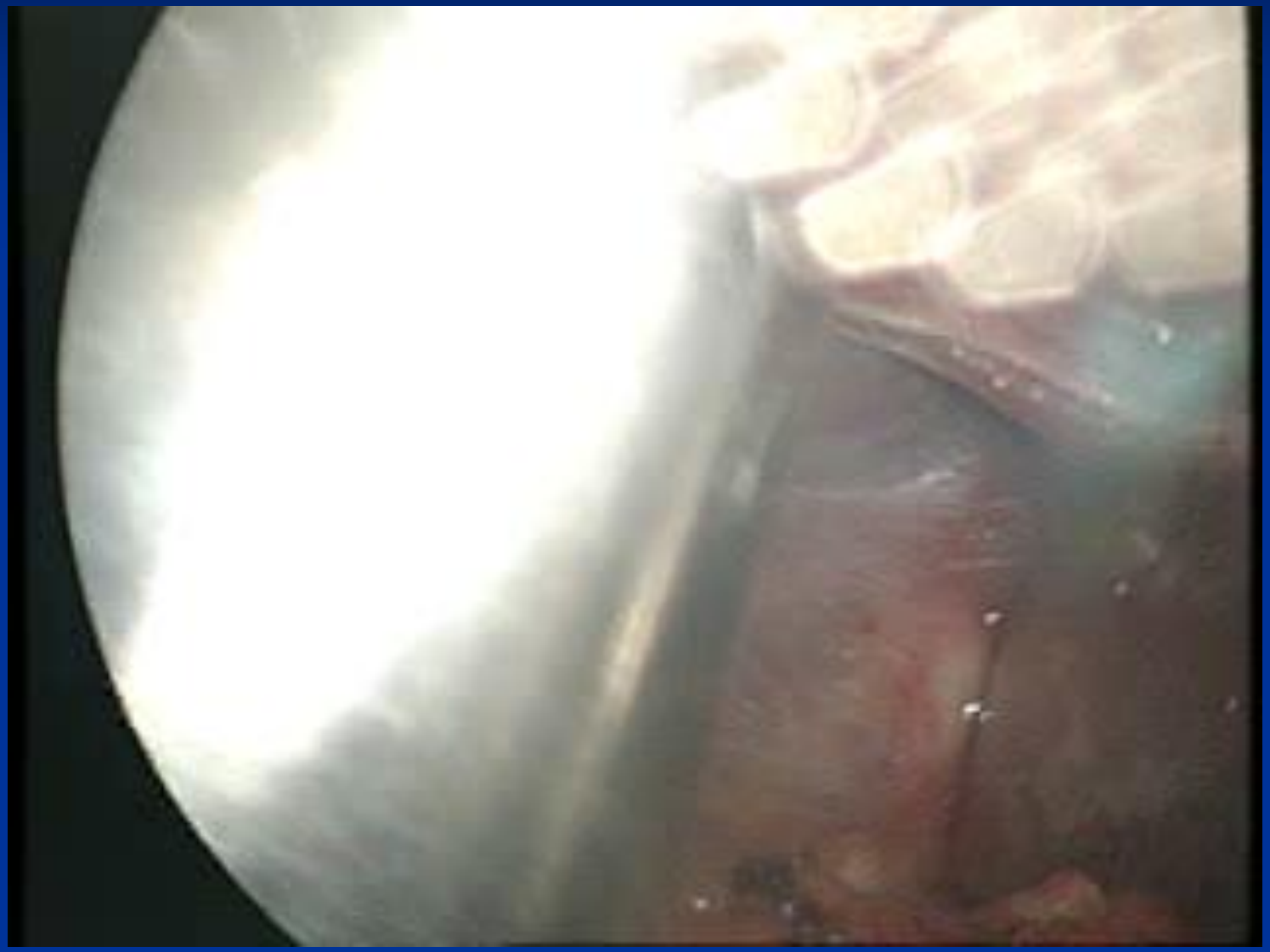

ID and Mobilization of RLN

Ligation of Arterial Supply

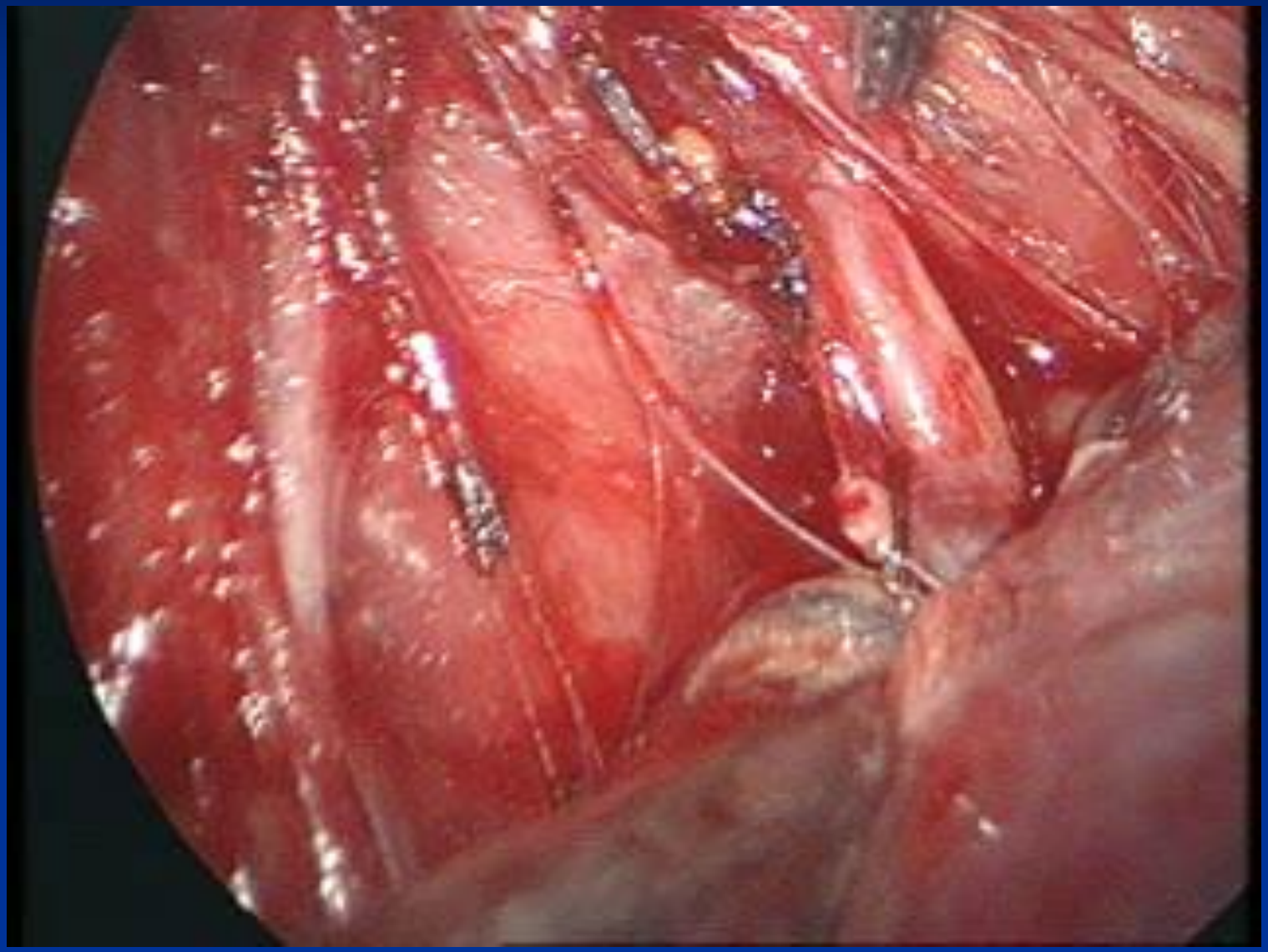

Adenoma

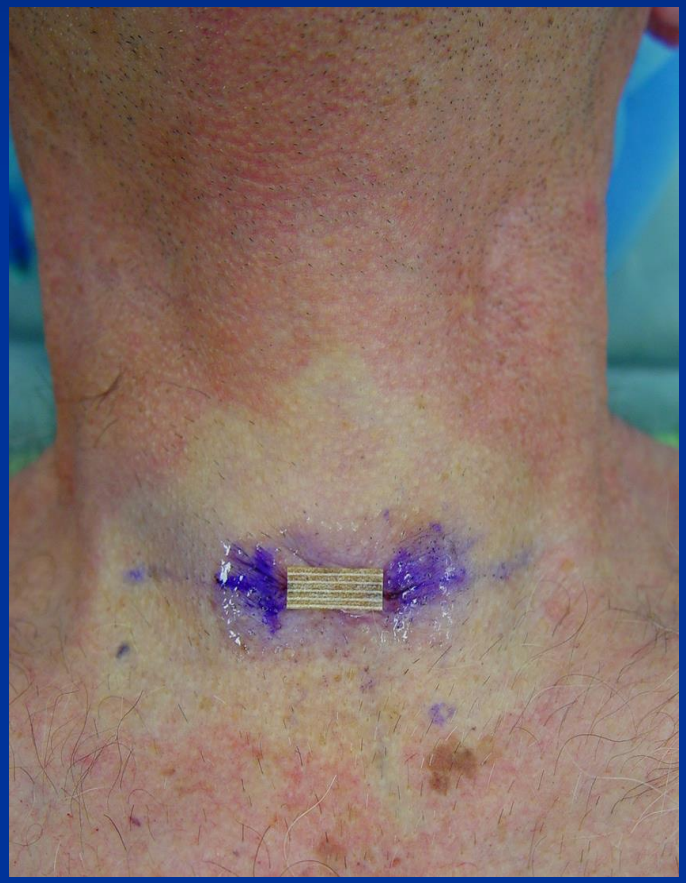

Glue and steri-strip

GRU
GEORGIA REGENTS UNIVERSITY
AUGUSTA

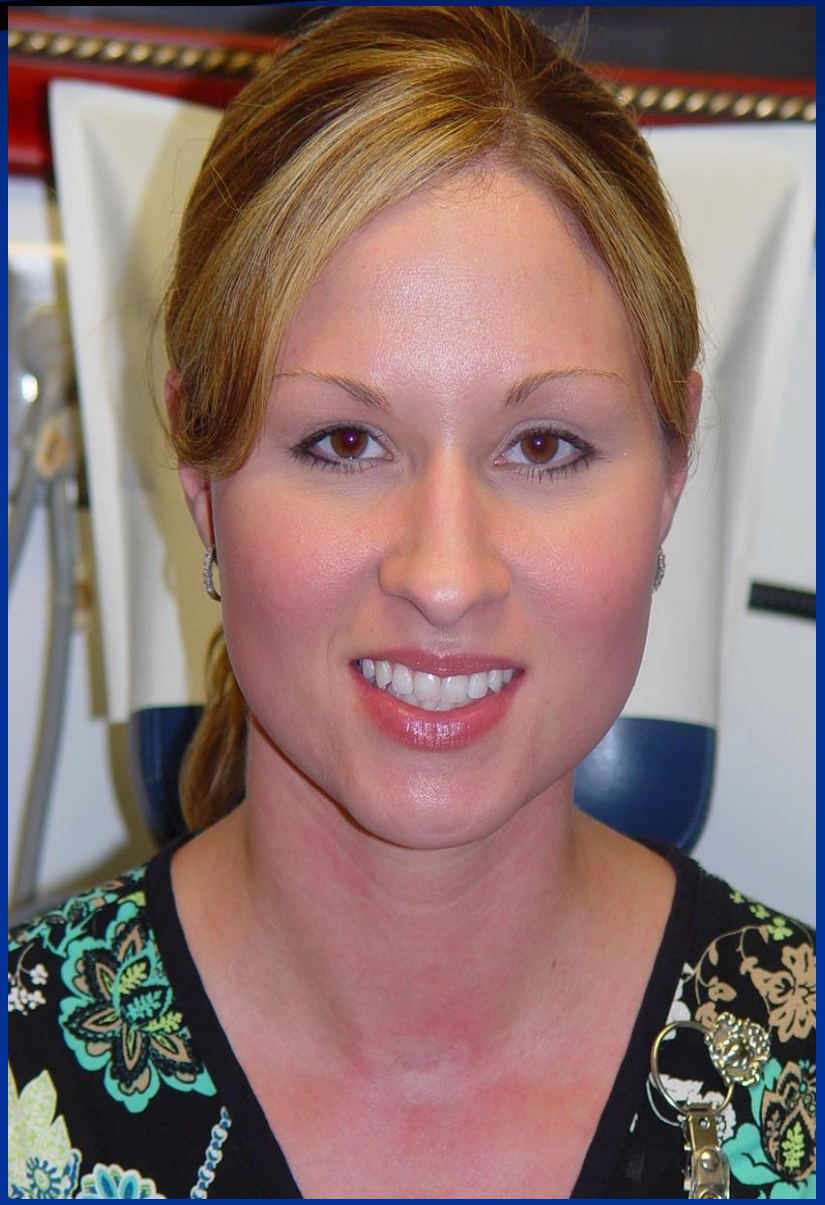


CM
1
2
3
4
1984

GRU
GEORGIA REGENTS UNIVERSITY
AUGUSTA

Know common hiding places

- "for a missing inferior gland, look superior to the superior gland"
- "for a missing superior gland, look inferior to the inferior gland"

Persistent Eucalcemic HPT

- In up to 40% of patients who undergo curative parathyroidectomy, PTH remains elevated for up to 12 months after surgery
- Vitamin D deficiency; renal dysfunction; normal glands finding new “set-point”
- 314 parathyroidectomies, 187 pHPT and single gland disease, 119 met criteria

Persistent Eucalcemic HPT

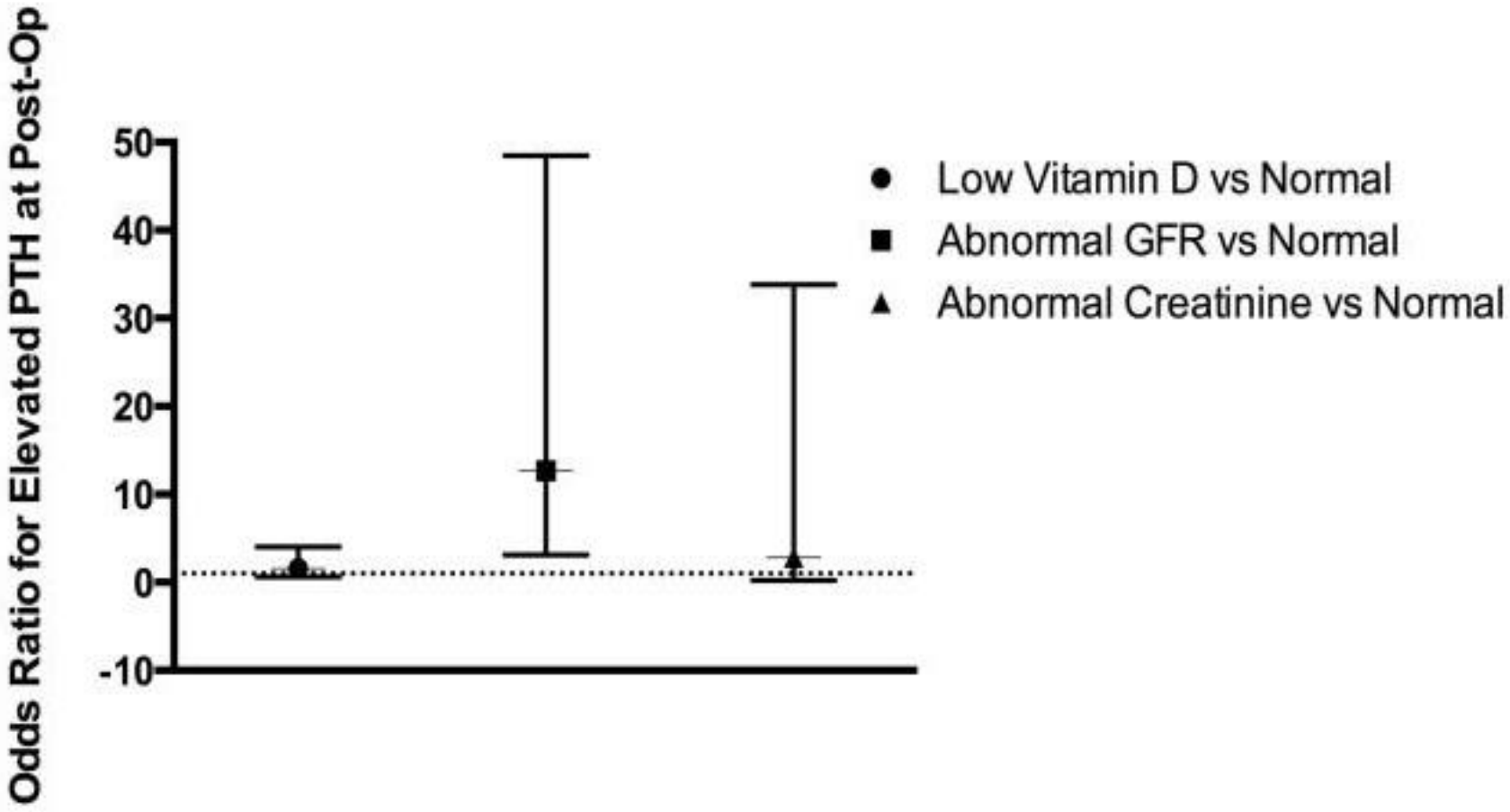

Observations

MIP Meaningful Advantages

- Reduced dissection
- Outpatient
- Lower rate of hypoparathyroidism
- Bilateral nerve injury eliminated
- Minimal incision (<15 mm)
- Comparable cure rates