NORTH CAROLINA DERMATOLOGY ASSOCIATION

2016 Summer Meeting

SATURDAY, JULY 9 PRESENTATIONS

JULY 8-10, 2016

THE LODGE AT COLONIAL WILLIAMSBURG
WILLIAMSBURG, VIRGINIA

This continuing medical education activity is jointly provided by the
North Carolina Dermatology Association and
Southern Regional Area Health Education Center

Practical Approach to Hyperpigmentation

North Carolina Dermatological Society
July 10, 2016

Seemal R. Desai, MD, FAAD
Clinical Assistant Professor
Department of Dermatology
University of Texas Southwestern Medical Center
Founder & Medical Director
Innovative Dermatology, PA
Dallas, Texas

Disclosures

- **No pertinent conflicts of interest in relation to this presentation**

- Galderma (C) (H)
- Symbio (R)
- Allergan (C) (H)
- Valeant Pharmaceuticals (C) (H)
- Abbott (C) (H) (R)

Hyperpigmentation

- **LOCALIZED**
  - **Post inflammatory Hyperpigmentation**
  - **Melasma**
- **DIFFUSE**
  - **Metabolic Causes**
    - **Vitamin Deficiencies like B12, Folate**
    - **Check Cortisol, TSH and Iron**
  - **Medications**
    - **Discontinue the offending agent**
  - **Malignant**
    - **Hx of Melanoma**
  - **Autoimmune and Infectious**
    - **Systemic Sclerosis, POEMS, PCT, HIV etc…**

Post inflammatory Hyperpigmentation & Acne

PIH Pathogenesis

- **Thought to be due to inflammatory mediators**
  - **Prostaglandins including PGE2**
  - **Leukotrienes including LTC4 and LTD4**
  - **All of which have been shown to stimulate epidermal melanocytes**
- **In turn, a disruption is noted in the skin's basal layer**
  - **→ dermal deposition of melanin and subsequent macrophage activation**

Taylor S et al. J Cutan Med Surg 2009

PIH

- **Treatment Options**
  - **FIRST AND FOREMOST**
    - **Treat any underlying underlying dermatoses and stress the important of sun protection**
  - **Topical Retinoids**
  - **Azelaic Acid**
  - **Hydroquinone**
  - **Chemical Peels**
  - **Cosmeceuticals**
  - **Reassurance and Time**

Case 1

Acne → PIH

- Tazarotene vs Adapalene for Post inflammatory
  - Controlled Blinded Trial of 180 patients
  - Investigators evaluated improvement of PIH and acne
  - Subjects included African Americans, Asians, and Hispanics
  - 20% of patients in the tazoretene 0.1% cream group had complete resolution at week 16
  - 7% of patients in the adapalene 0.3% gel group
  - Tazoretene 0.1% cream was more effective than Adapalene 0.3% gel in reducing PIH

Tanghetti E et al. JDD May 2012

Case 2

Melasma

- Risk Factors
  - Sunlight
  - Pregnancy
  - Genetic predisposition
  - Hormonal contraceptives
  - Cosmetics
  - Endocrine issues
  - Thyroid dysfunction
  - AND NEVER FORGET MEDICATIONS!!

Hydroquinone Safety

- The supervised use of prescription topical hydroquinone had no more than a theoretical risk of malignancy, developing ochronosis or other long term safety side effects
- No substantial evidence to prove its carcinogenicity
- TAKE THE TIME TO DISCUSS LONG TERM USE WITH EACH OF YOUR PATIENTS !!

Nordlund JJ, Grimes PE, Ortonne Jp JEADV 2006; 20.781-7

Melasma

- Triple Combination Fixed Therapy
  - Multicenter RCT of Southeast and East Asian patients
  - 260 patients → 129 in Triple combo group
  - 260 patients → 131 in Hydroquinone only group
  - 8 weeks treatment
  - Assessed by Melasma GSS, MASI, patient satisfaction
  - Triple combo had superior efficacy to monotherapy in GSS and other variables but more adverse effects

Chan R et al, BJD 2008

Melasma
Second Line Topical Agents

- **Azelaic Acid**
- **Kojic Acid**
- **Zinc**

Melasma

- **Azelaic Acid**
  - **Prospective, single blinded, right left comparison study**
  - **40 Indian patients with melasma**
  - **BID application of 20% AZA cream to one half of face for 24 weeks**
  - **Second half had application of Clobetasol 0.05% for 1st 8 weeks followed by 20% AZA cream for next 16 weeks**
  - **Sequential therapy had more significant improvement than monotherapy side ($p<0.01$)**

Sarkar R, Dermatology 2002; 205:249-54

Melasma

- **Kojic Acid**
  - **Produced by *Aspergillus oryzae***
  - **Tyrosinase inhibitor and photo protective effect**
  - **More clinically stable molecule but with weaker lightening properties**
  - **Comparative study showed that Glycolic Acid with kojic acid and Glycolic acid with hydroquinone were effective in treatment of melasma**

Garcia A et al Dermatol Surg 1996; 22:443-7

What are some newer global therapies?

Kojic Acid Dipalmitate

- Antibiotic produced by many species of aspergillus and penicillium
- Unlike kojic acid, **kojic dipalmitate is more stable to light, heat, pH and oxidation, and also compatible with most organic sunscreens.**
- *MOA*: inhibits tyrosinase
- **More efficacious than kojic acid.**

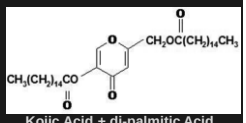

Kojic Acid + di-palmitic Acid


Aspergillus oryzae (koji) growing on rice

Melasma

- **Topical Methimazole**
  - **A potent peroxidase inhibitor leading to morphologic change in melanocytes**
  - **Kasraee et al showed 20 patients with no TSH, free thyroxine or free iodothyronine levels**
  - **Prepared by dissolving MMI in distilled water and placing in a cream base to make a final concentration of 5% qhs for 8 weeks**

Abbas et al. Dermatol Ther 2013 Jan;26(1):69-72

Glutathione

- **Binds to the copper containing active site of tyrosinase and thereby inactivates the enzyme**
- **Potent antioxidant → indirect inactivation of tyrosinase**
- **Assists in converting eumelanin → to phaeomelanin**
- **Typically used orally**
  - **Most commonly in doses of 500mg BID, and is also being given IV in Asia.**
  - **Still controversial due to bioavailability, but some promising results in studies**

Allen J et all. J Altern Complement Med 2011; 17:827-33

Oral Antioxidants

- **A number of different options available**
  - Green tea extracts, Procyanidin, oral zinc supplementation
- ***Polypodium leucotomas*, orally administered**
  - 240mg taken 3 times daily for 12 weeks
  - Though it is a potent anti-oxidant from a fern
  - No significant difference compared to placebo

Ahmed AR et al, JAMA Dermatology 2013; 149:981-983

Assessment of a Superficial Chemical Peel Combined With a Multimodal, Hydroquinone-Free Skin Brightener Using In Vivo Reflectance Confocal Microscopy

Goberdhan et al., 2013

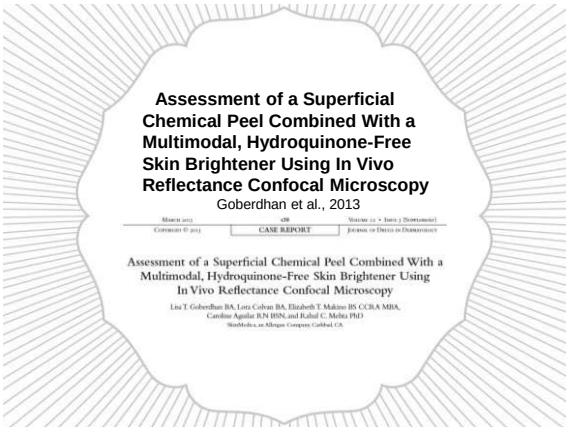
CASE REPORT

Assessment of a Superficial Chemical Peel Combined With a Multimodal, Hydroquinone-Free Skin Brightener Using In Vivo Reflectance Confocal Microscopy

Chemical Peels & Melasma

Peels in Melasma

- **Glycolic Acid 30-50% → 5-6 peels q2-3 weeks**
- **Salicylic Acid Peels 15-30% → 5-6 peels q2-3 weeks**
- **Trichloracetic Acid Peels 10-15%**
  - Can prime skin with Glycolic and then follow with TCA
  - Although, commonly use 10-15% in Types IV-VI

Do Lasers work in the treatment of melasma?

Laser Therapy

- 27 female subjects, phototypes II–V
- Mixed-type melasma refractory to previous therapies
- Low-fluence QS Nd:YAG laser treatment of 1.6–2 J/cm^2 with 5 or 6 mm spot was administered immediately following microdermabrasion.
- Daily application of a broad-spectrum sunscreen began immediately
- Subjects used a topical skin care regimen of hydroquinone with tretinoin or vitamin C. Treatments were repeated at 4-week intervals

Kauvar et al. Lasers in Surg and Med. 44:117-24 (2012)

Melasma

- Pigmentary Disorders Academy
  - First line therapy
    - Topicals with Triple Combination
  - Should patients develop irritation/allergy to triple combination therapy
    - Dual Combinations can be used
  - Second line therapy
    - Chemical Peels in combination with topicals

J Am Acad Dermatol 2006;54: S272-81

Clinical Cases

Psoriasis in Skin of Color

- Clinical Features
  - Differential diagnosis includes
    - Lichen Planus
    - Cutaneous Lupus
    - Severe Fungal Infections
    - Sarcoidosis
    - Infectious causes

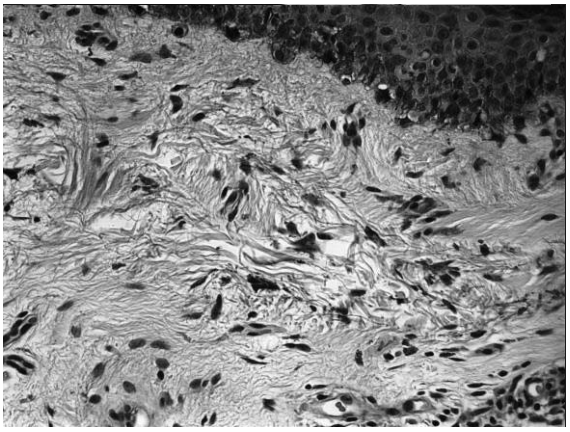

What I do

- Detailed History
  - Detailed medication history
  - +/- Family History
  - Previous treatments
  - Cosmetics/Fragrance Based Products
    - I do patch test when suspicious
- Take Serial Photographs
  - Pre-treatment and during
  - Dark Background
  - Patients tend to often think "its not working"
- Empathize
  - Will increase your credibility and rapport dramatically
- Biopsy
  - Do not be scared to if needed
  - 2mm punch to elucidate dermal vs epidermal vs other processes (!)

What I do

- Treatment
  - Topical triple combination therapy
    - My own compound containing HQ, Kojic Acid, Triamcinolone and Tretinoin in special base
  - Add on chemical peels
    - Start with Salicylic Acid → can help concomitant acne
    - Otherwise, studies favoring glycolic acid
  - I do increase the percentage strength of hydroquinone if needed
  - Dermabrasion for special cases
  - ALWAYS EMPHASIZE UV PROTECTION EVEN IN SOC

Take Home Messages

- Pigmentary Disorders continue to be a large part of a busy medical dermatology practice
- More randomized controlled trials are needed to evaluate the efficacy of up and coming treatments in the diagnosis, management and treatment of conditions such as melasma and vitiligo
- Always take a step back and try to establish the underlying pathology

Questions / Comments

Seemal R. Desai, MD
Clinical Assistant Professor
Department of Dermatology
University of Texas Southwestern Medical Center
Dallas, Texas

Innovative Dermatology, PA
www.innovative-dermatology.com
seemald@yahoo.com

Cutaneous Infections and Infestations

Dirk Elston MD
Professor and Chairman
Department of Dermatology and Dermatologic Surgery
Medical University of South Carolina

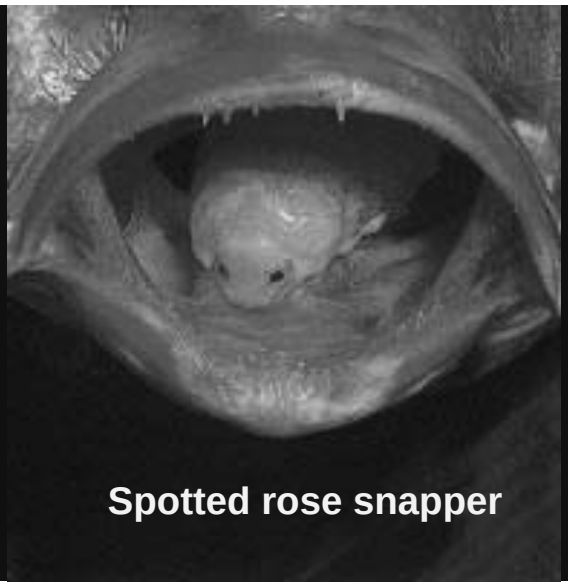

Spotted rose snapper

Cymothoa exigua

Tongue Worm (Pentastomiasis)

- *Armillifer* and *Linguatula* are wormlike arthropods endemic to Asia and Africa.
- In human, severe inflammation, coughing hemoptysis, lacrimation, coryza, and facial edema. Rarely asphyxiation.

42% of triatomes collected in and arounds homes in Tucson
PCR positive for *T cruzi*
Emerg Infect Dis 2010;March

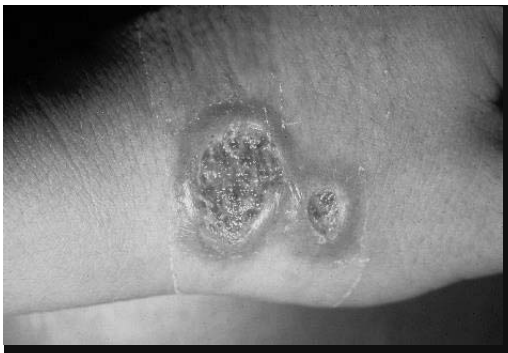

Leishmaniasis

Sandfly

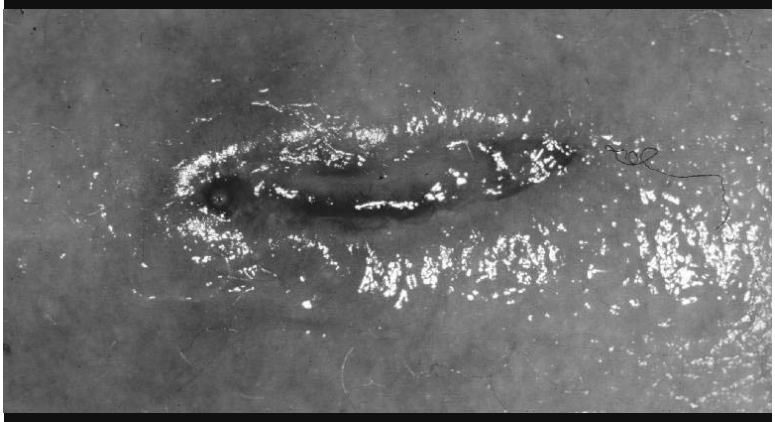

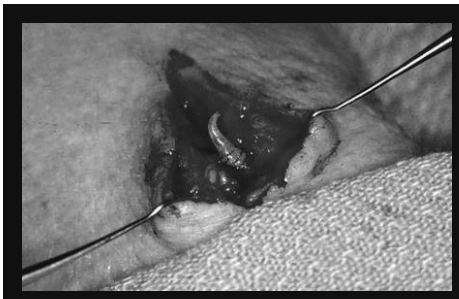



Occlusive agents:
Bacon
Surgilube
Chimo

American Academy of Pediatrics

- Recommends no more than 30% DEET
- Off Skintastic and others

New trends

- Stabilized DEET/sunscreen
  - Increased absorption
- **Picaridin** (KBR3023, Bayrepel, Cutter Advanced)
  - **C**omparable in efficacy
  - Less irritating than DEET

Crawling Arthropods:



Hyalomma ticks: Crimean-Congo Hemorrhagic Fever

Resistant Lice and Treatment Failure

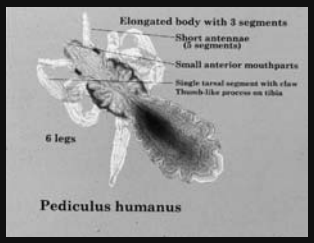

Knockdown resistance

- - Permethrin
  - Lack of immobilization, related to sodium gated channels
-

Drug Risks

- Congenital leukemia with a 11q23/MLL rearrangement
- Because of arachnophobia, the mother had heavily abused aerosolised permethrin
- Incubation of the BV173 cell line with permethrin induced MLL cleavage

- Arch Dis Child Fetal Neonatal Ed. 2003 Sep;88(5):F436-7

Drug Risks

- Childhood leukemia associated with
  - Insecticide use during pregnancy
  - Insecticide exposure during childhood
  - Garden insecticide use
  - Use of insecticidal shampoo

- Occ Environ Med 2006; 63:131-4

Alternatives to Drug Treatment

- Wet combing (“bug busting,)
  - Cure rate for only 38%
- Hot blow dryer
  - 30 minutes

Nit removers

New agents

- **Ulesfia** - benzyl alcohol lotion 5%
  - 6 months and older
- Natroba – Spinosad, benzyl alcohol
  - Derived from a soil microbe
  - Age 4 and older
  - 10 minutes, no nit combing (for now)
  - Skin and eye irritation (2%)

Pediatrics. 2009 Sep;124(3):e389-95

Asphyxiators

- Benzyl alcohol lotion 5% (**Ulesfia)**
  - **100% cure in phase II trial**
- Silicone oil: 92% dimeticone
  - 97.2% vs. permethrin 67.6% ($p < 0.0001$)

- BMC Infect Dis. 2008 Sep 10;8:115

Benzyl Alcohol Toxicity

- Intravenous administration
  - Neonates and low birthweight infants.
- "Gasping syndrome"
  - central nervous system depression, metabolic acidosis, and gasping respirations
  - Benzyl alcohol dosages >99 mg/kg/day

Benzyl Alcohol Toxicity

- Topical administration
  - Scalp itching and eye irritation
  - Plasma levels in 4 out of 19 subjects (21%)
  - The level ranged from 1.97 to 2.99 mcg/mL.
  - Similar range for both Ulesfia and Natroba

Essential Oils

- 3 botanical shampoos more effective than carbaryl
  - *Zanthoxylum limonella* Alston, *Acorus calamus* Linn., and *Phyllanthus emblica* Linn
- Several compare favorably to malathion

- Parasitol Res. 2014 Sep;113(9):3241-50.
- Trop Biomed. 2013 Jun;30(2):315-24.

Ivermectin versus Malathion

- *812 patients*
- *Ivermectin 400 microgram per kg or topical 0.5% malathion on days one and 8*
- *Ivermectin performed better 97.1% vs 89.8%, p=0.002)*

- N Engl J Med 2010; 362:896-905

Scabies

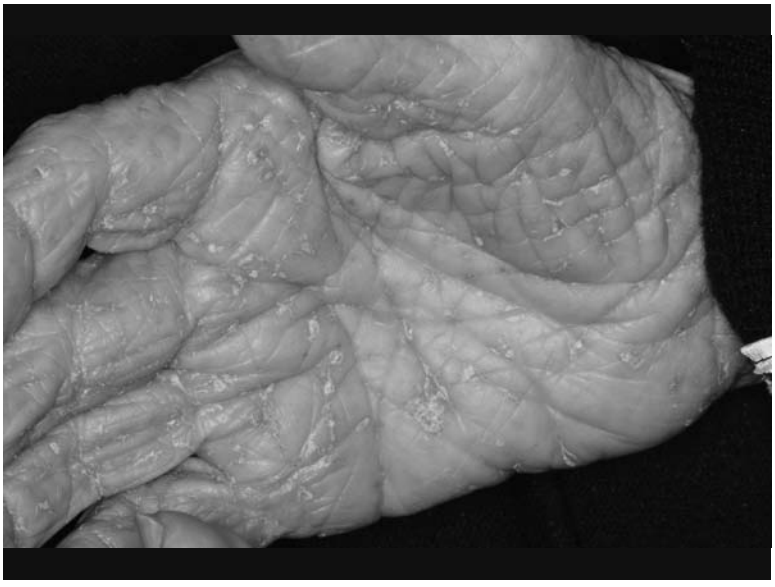

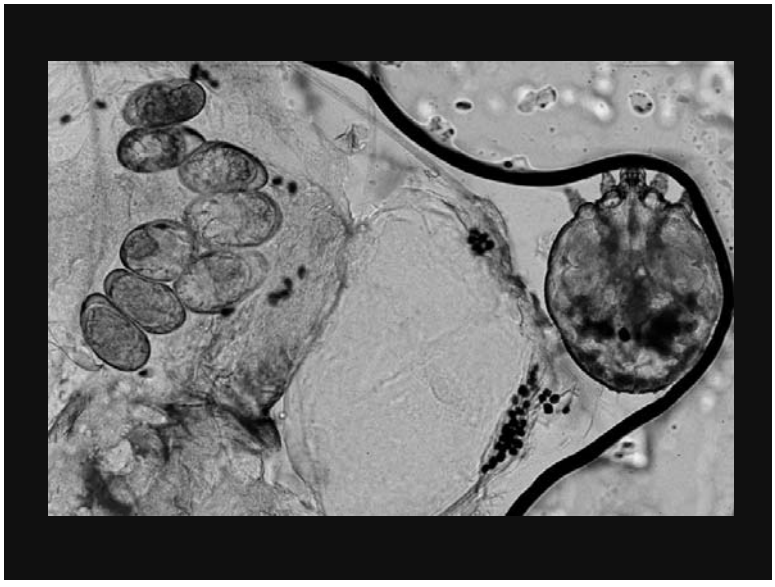



Courtesy of Jeff Meffert, MD

DIF:
Used to increase sensitivity of scrapings
Skin biopsy DIF may mimic pemphigoid

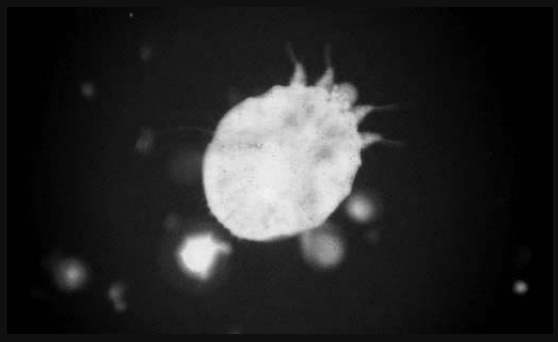

Treatment of scabies

- Permethrin 5%
- Lindane (seizures, aplastic anemia)
- Crotamiton (failure rate high)
- Benzyl benzoate
- 10% sulfur in petrolatum
- Ivermectin

Benzyl benzoate and Aloe

- BB compares favorably to other topicals and oral ivermectin
- Aloe vera gel compares favorably to BB in the treatment of scabies and may represent a less toxic alternative.

- Bull World Health Organ. 2009;87(6):424-30.
- Phytother Res. 2009;23(10):1482-4.

Crusted Scabies:

Repeated treatments
Oral/topical
Fomite control

Corbett. Genitourinary Med 1996; 72:115

Courtesy Joe English, MD

Courtesy Joe English, MD



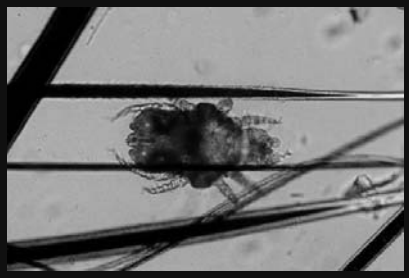

Cheyletiella

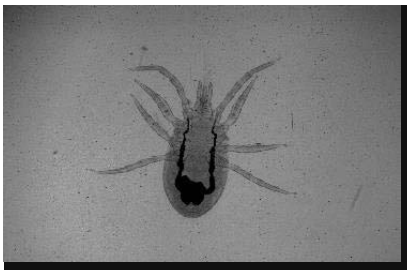

Zoonotic mites

60 year old female

- Found an 18 year old bottle of eye drops in her medicine cabinet

60 year old female

- Found an 18 year old bottle of eye drops in her medicine cabinet
- Decided to use them



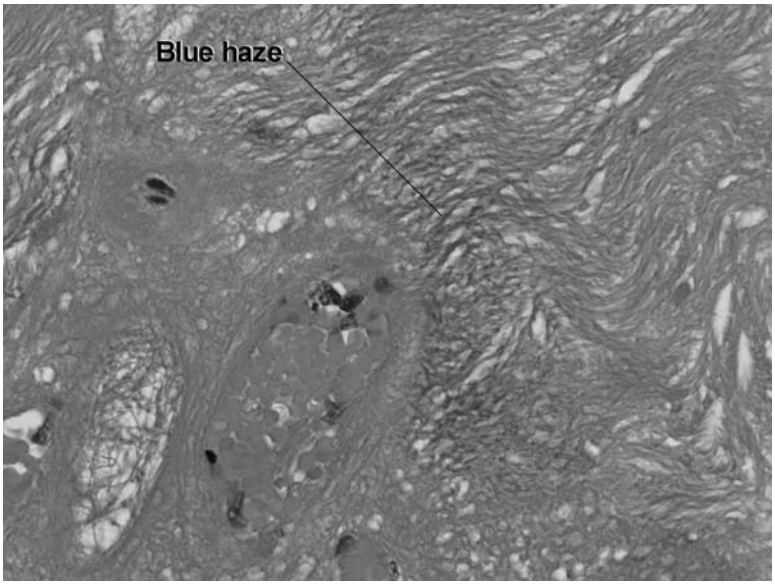

Pseudomonas Sepsis

- Pseudomonas endophthalmitis
- Unresponsive to systemic antibiotics
- Globe removed
- Survived sepsis after surgery and aminoglycoside therapy

34 year old female

- Unresponsive tinea pedis



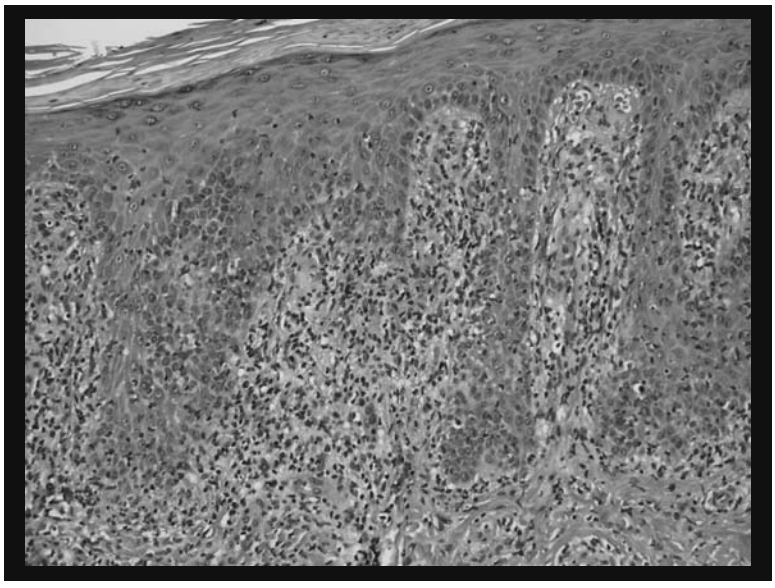

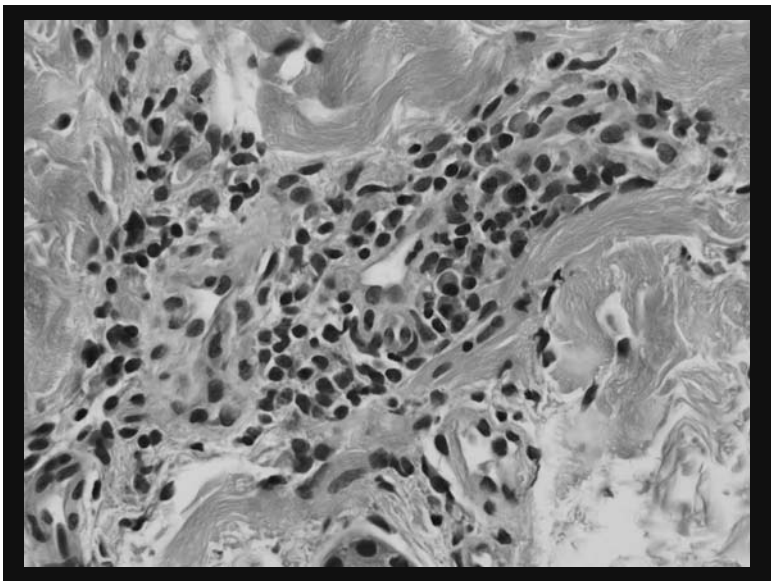

Secondary Syphilis with Prozone Phenomenon

RPR negative

1:64 dilution positive

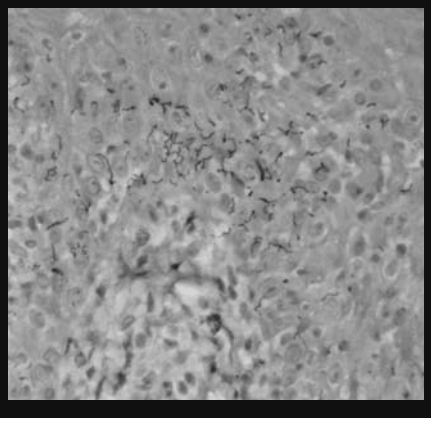

Syphilis

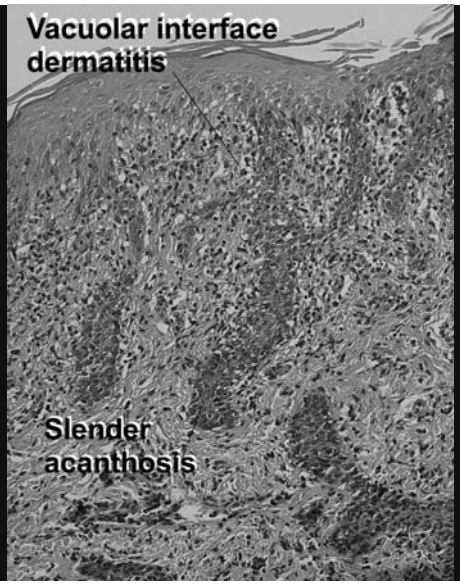

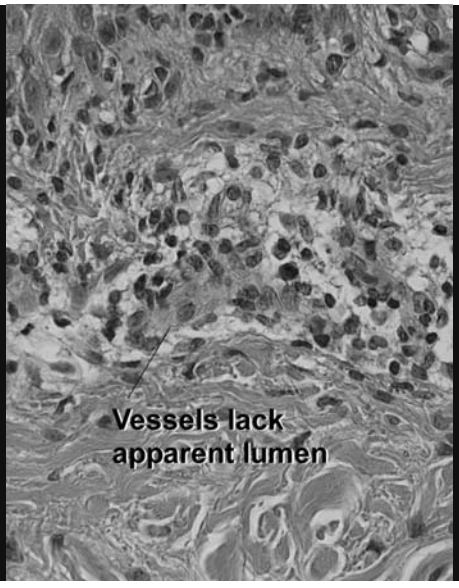

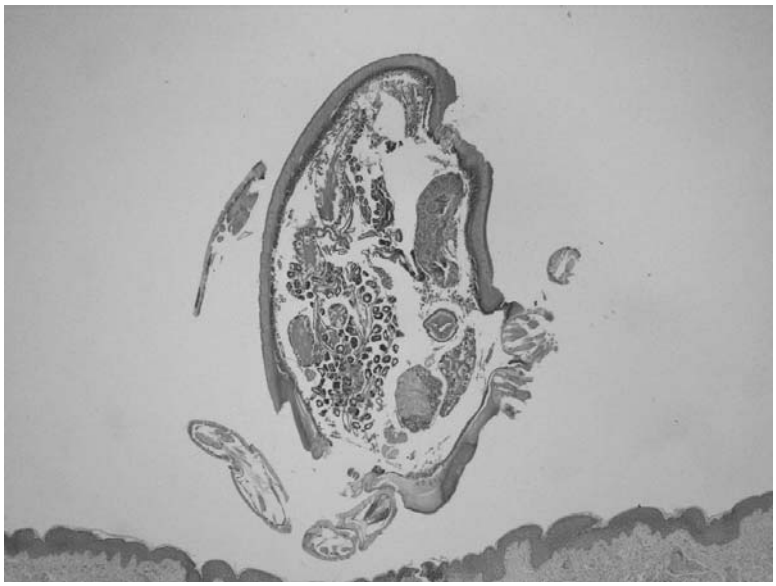

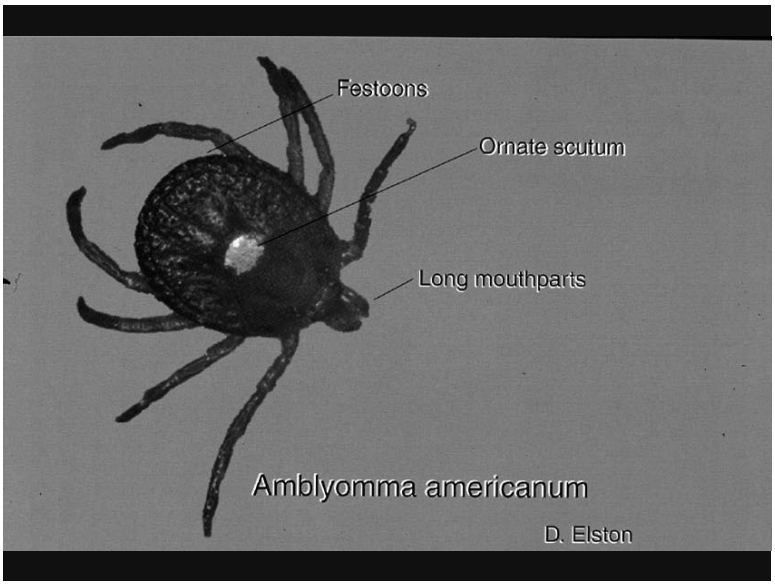

Lone star tick (*Amblyomma americanum*)

- Range expanding
- Larvae can attach by the thousands
- RMSF
- Tularemia
- Human monocytic ehrlichiosis (HME)
- *Ehrlichia ewingii* ehrlichiosis
- Southern tick-associated rash illness (STARI)

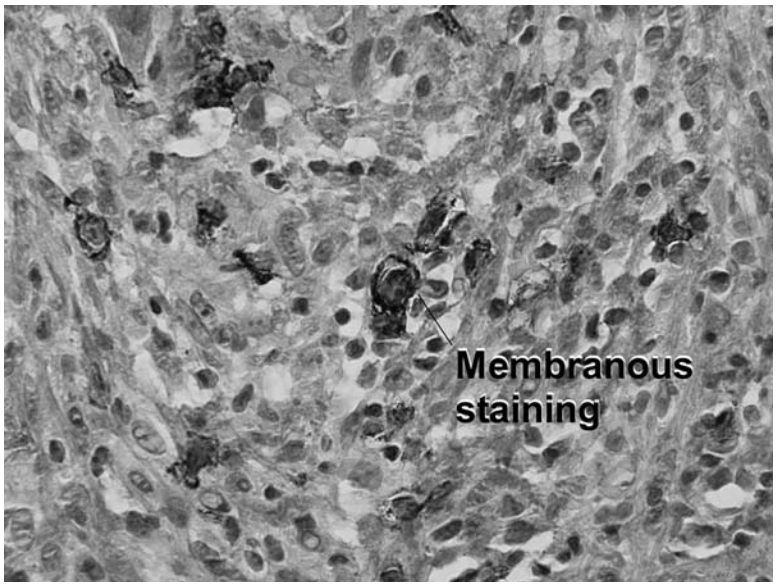

60 year old grandfather with pruritus

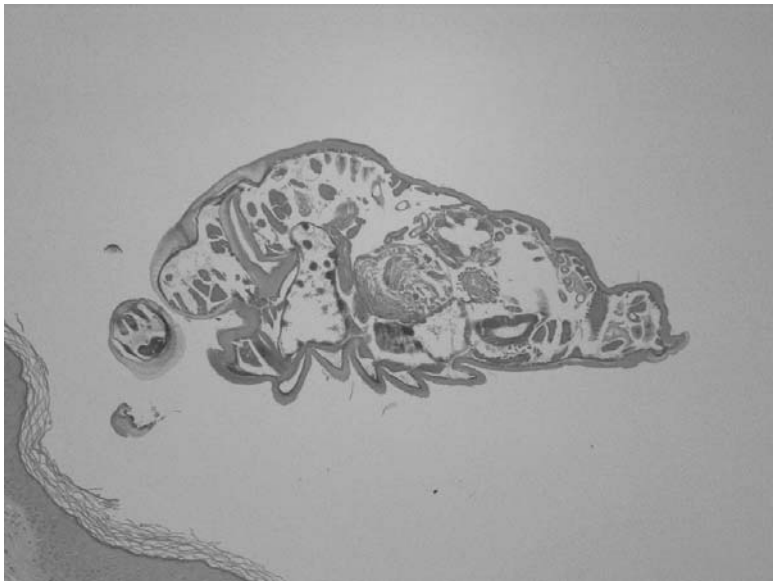



2 year old Being Treated for Langerhans Cell Histiocytosis

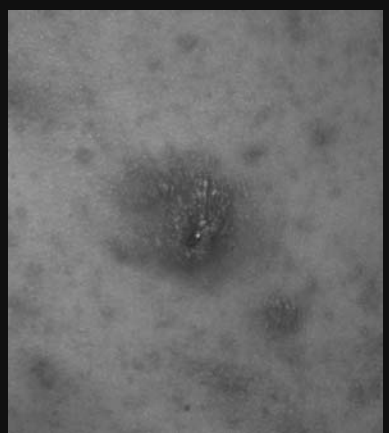

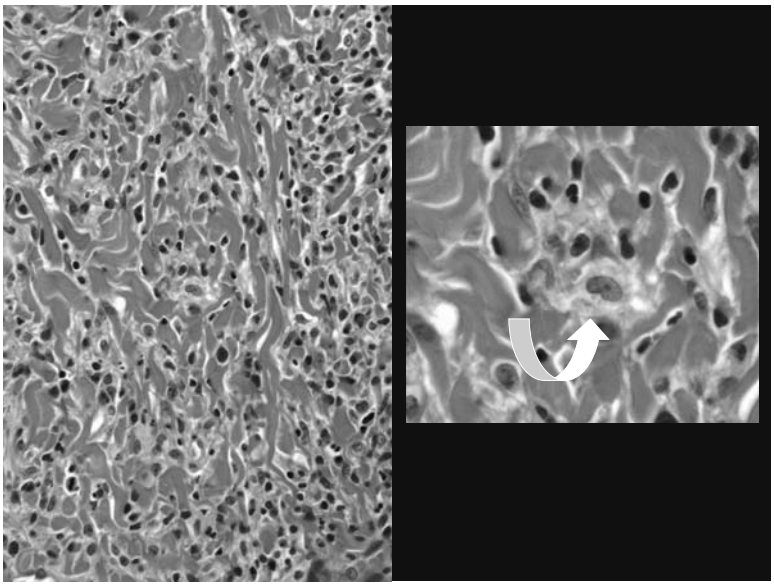

Scabies Mimicking LCH

- Pediatr Dermatol. 2004 Jan-Feb;21(1):58-62.
- Clin Exp Dermatol. 2003 Jan;28(1):111-2.
- Med Pediatr Oncol. 2003 Feb;40(2):111-2.
- Pediatr Dermatol. 1994 Dec;11(4):327-30.
- An Esp Pediatr. 1984 Feb 15;20(2):121-5.

7 year of female

- 7 cm mass on scalp with draining sinus tracts

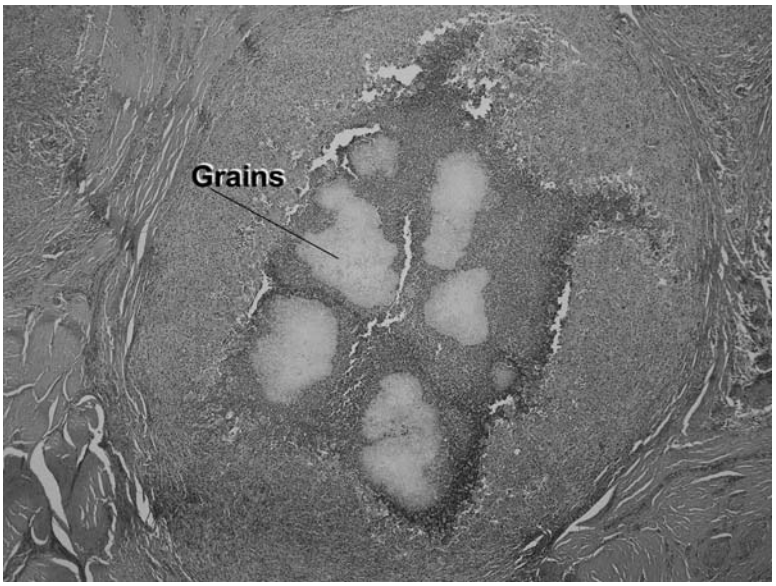

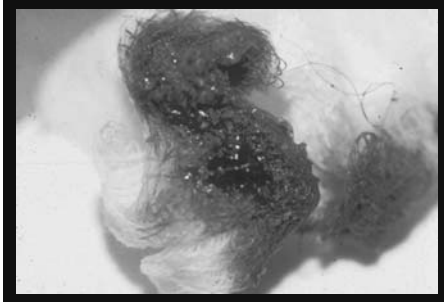

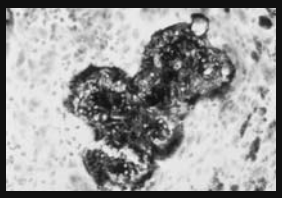

Microsporum canis

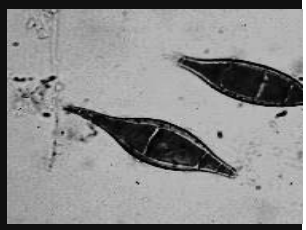

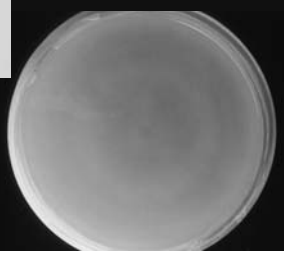

- In foster care
- Adopted a stray kitten

100 year old man

- Lesion on the arm
- Case donated by Antoinette Hood, MD

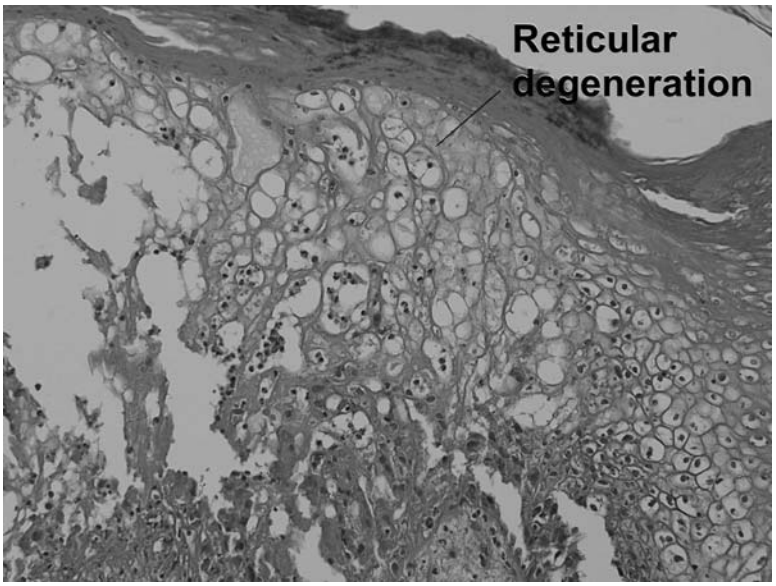
Reticular
degeneration

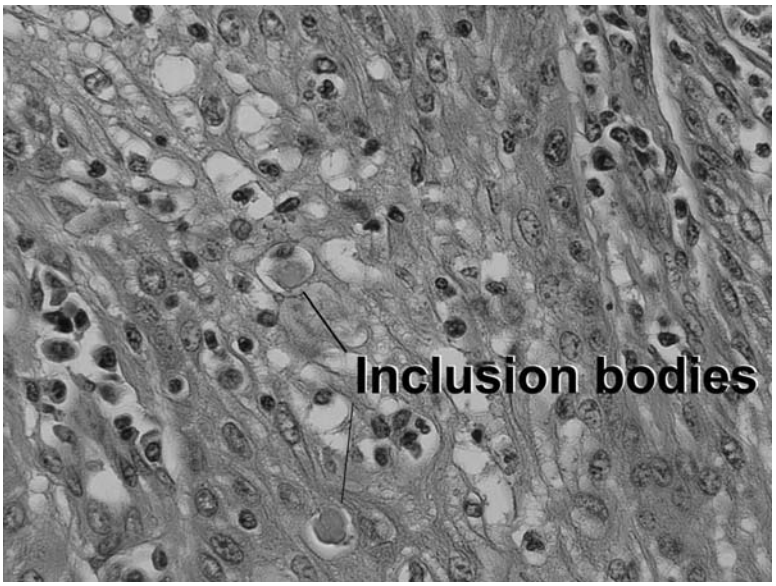
Inclusion bodies

Brown recluse (*Loxosceles reclusa*)

Brown spider bites:
L. reclusa, L. laeta

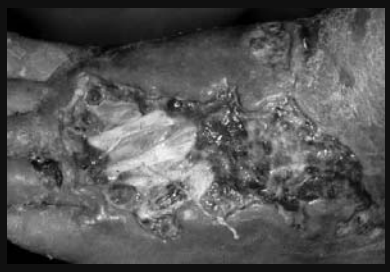

Sphingomyelinase D, hyaluronidase
Arthus rxn, PAN-like arteritis

Treatment:
Rest
Ice
Elevation
Antiobiotics
Debridement

(Dapsone, ASA, Prednisone, Cochicine)

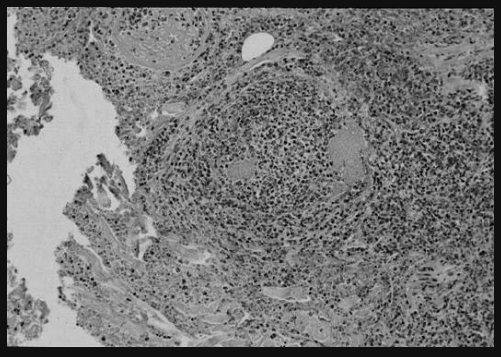

Black widow
(*Latrodectus mactans*)

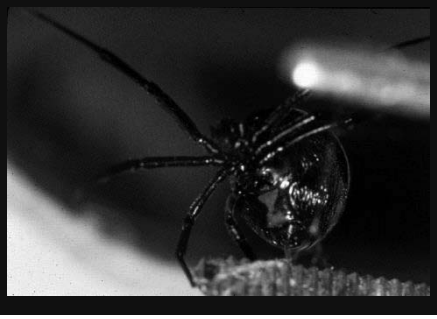

Black widow

- Toxicity can be long-lasting
- Valium
- Calcium gluconate
- Antivenin: Can be beneficial even days after the bite

Tarantulas (Theraphosidae)

Contact urticaria

Ophthalmia nodosa

Centruroides sp.





Texas grasshoppers
ready for BBQ

Arilus sp.



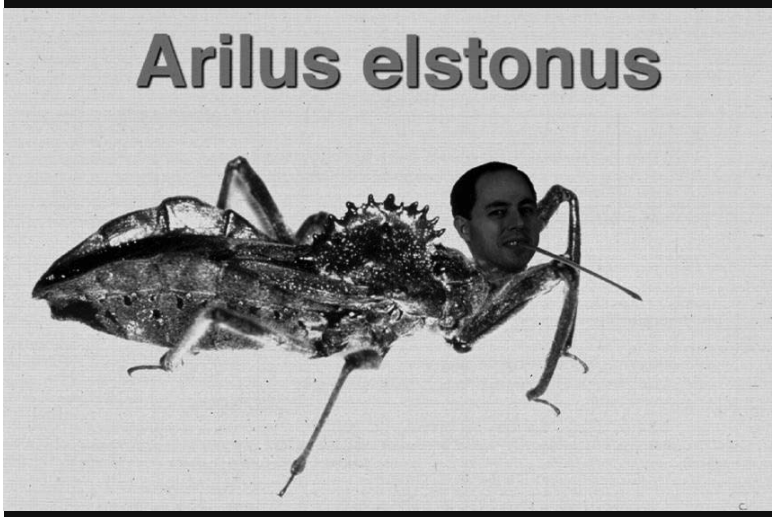

5 year old female

- Multiple subcutaneous nodules

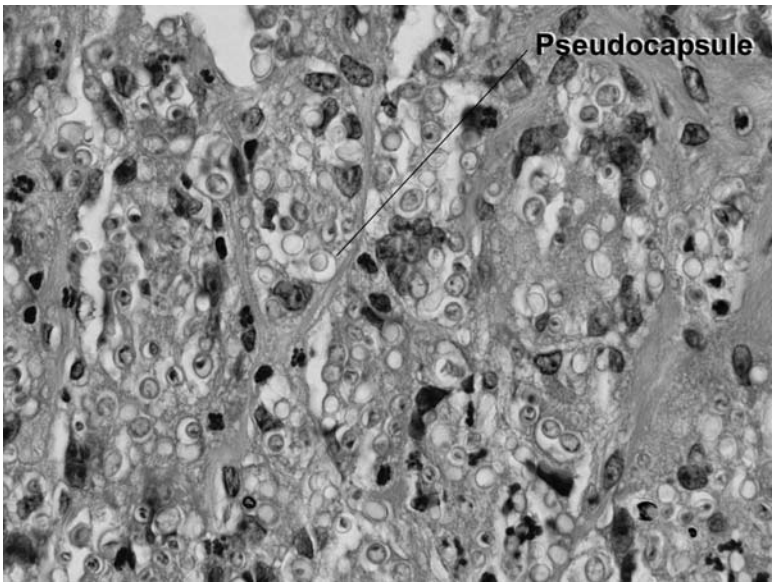

Histoplasma capsulatum

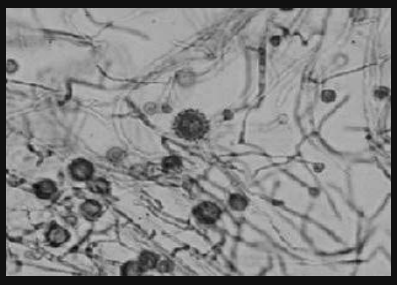

Macroconidia are echinulate (tuberculate)

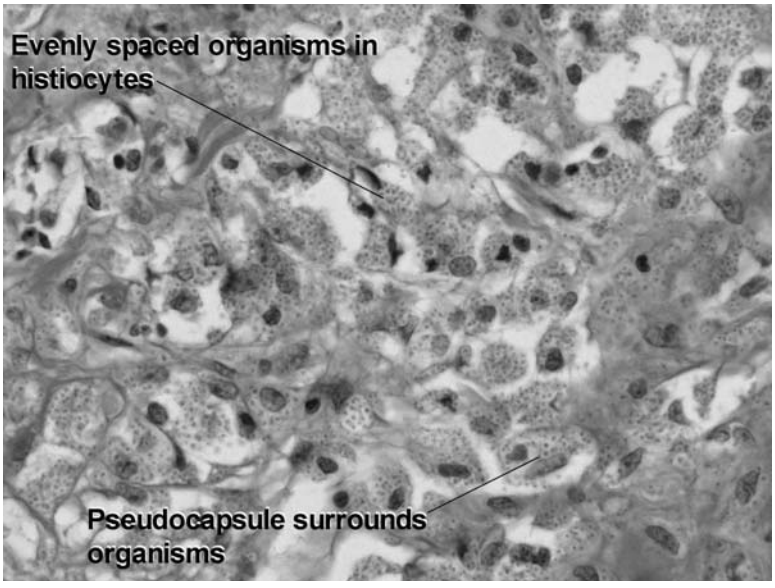

African Histoplasmosis

- Key features
- -Numerous large intracellular organisms in histiocytes and multinucleated giant cells
- -Evenly spaced distribution of organisms in giant cells



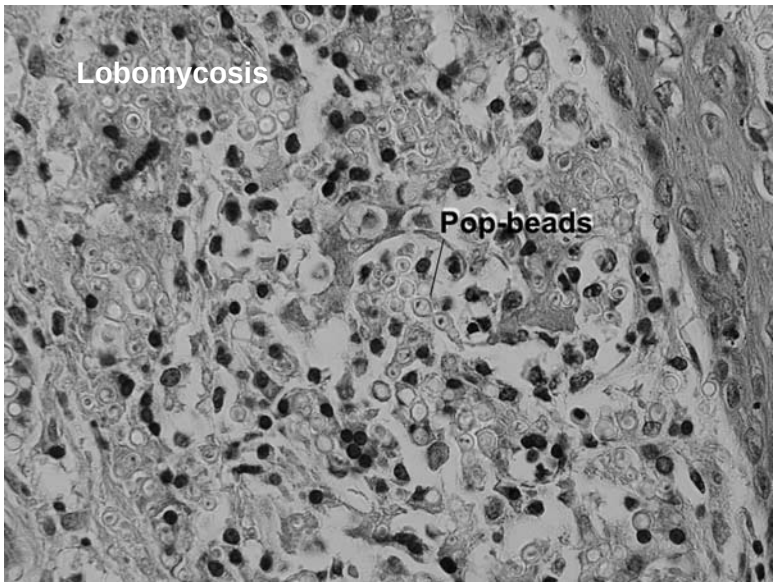
Lobomycosis
Pop-beads

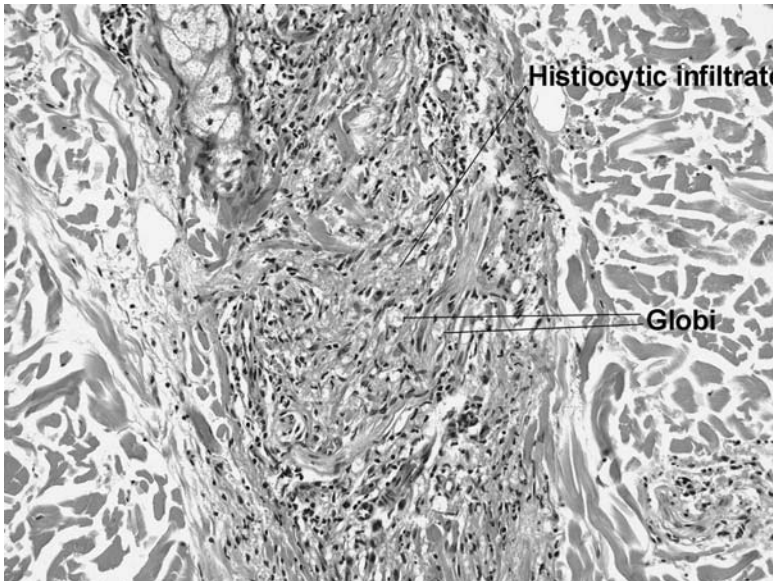
Histiocytic infiltrat
Globi

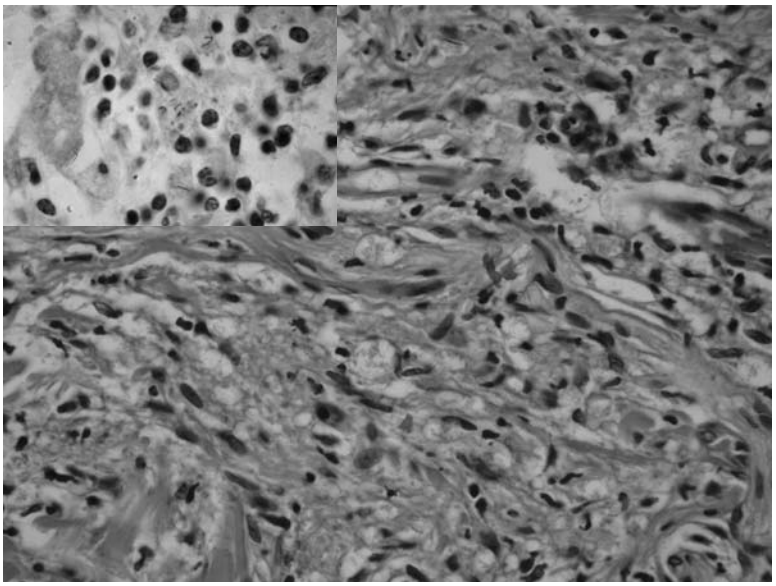

Hansen's disease:



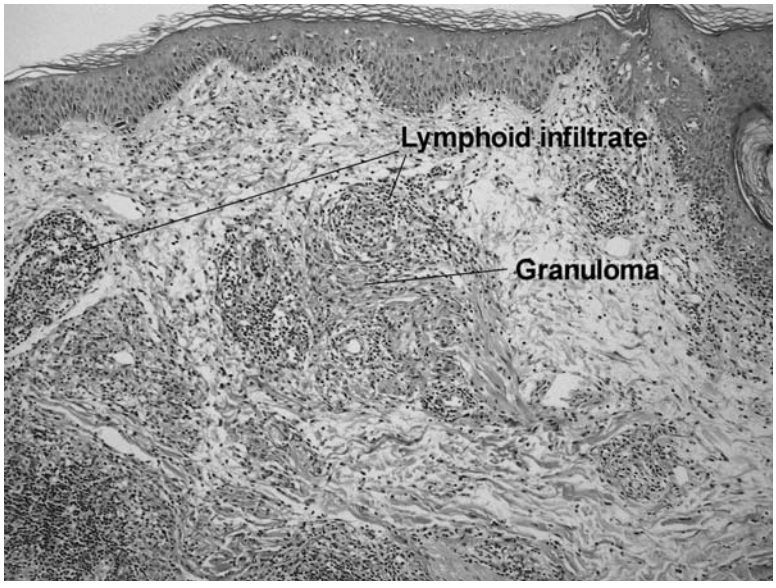

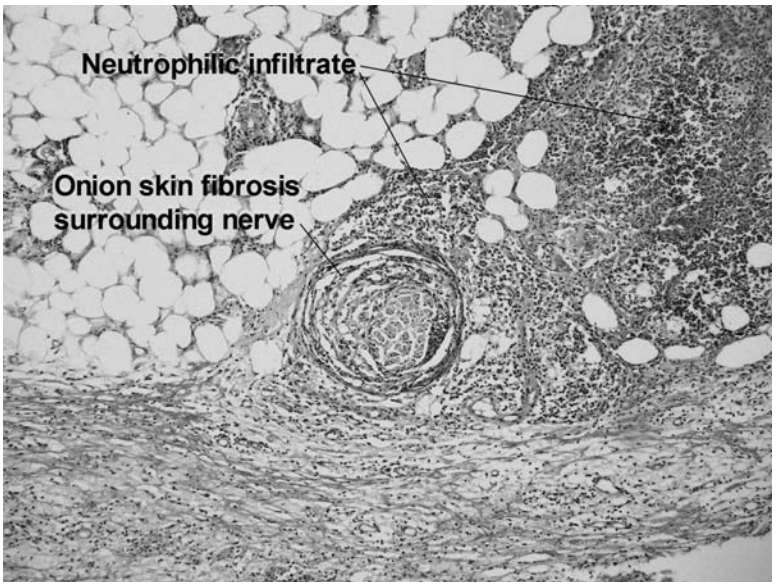
Neutrophilic infiltrate
Onion skin fibrosis
surrounding nerve

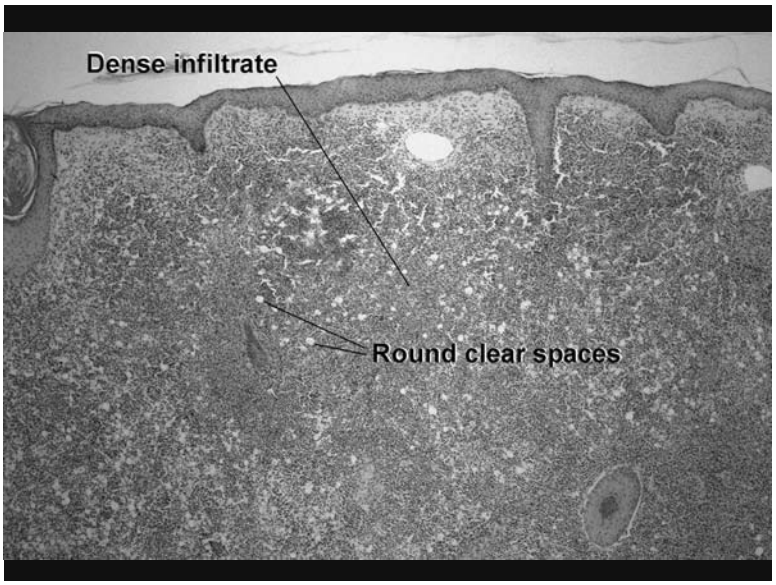
Dense infiltrate
Round clear spaces

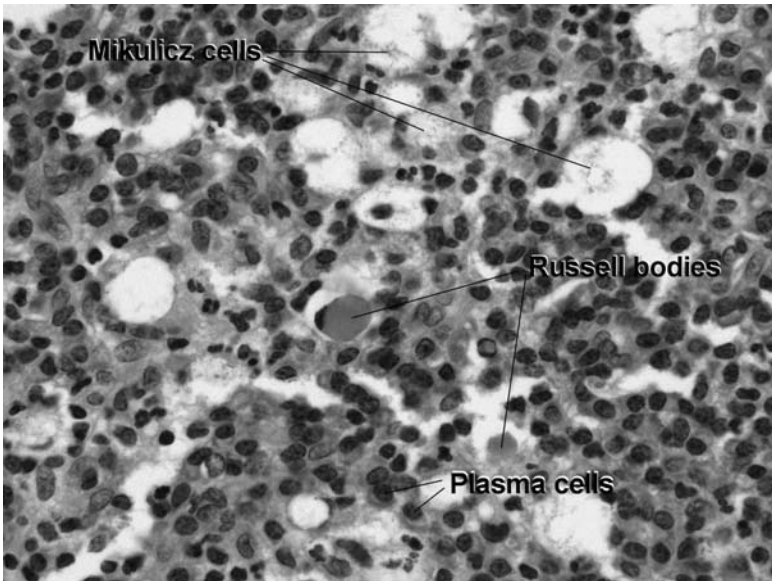
Mikulicz cells
Russell bodies
Plasma cells

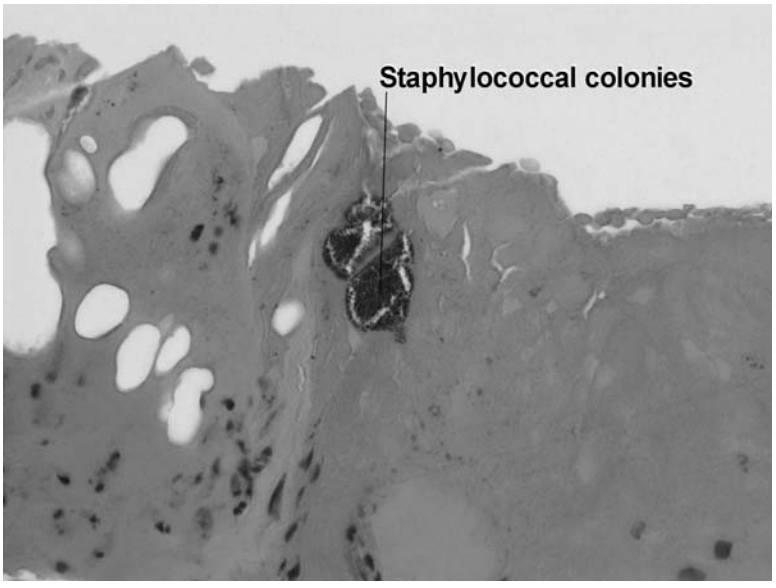
Staphylococcal colonies

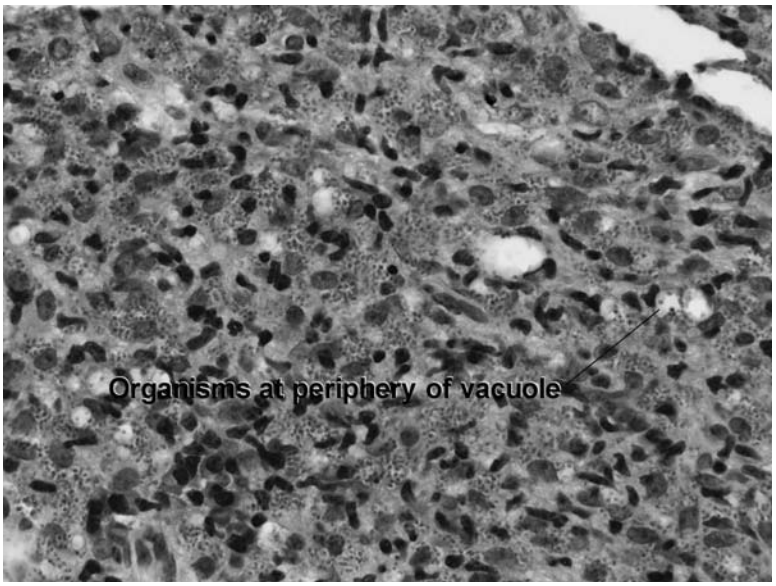
Organisms at periphery of vacuole

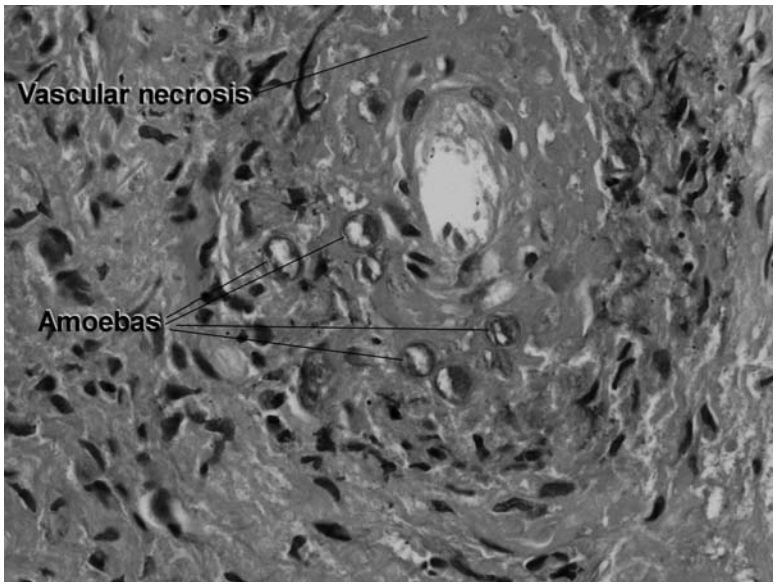
Vascular necrosis
Amoebas

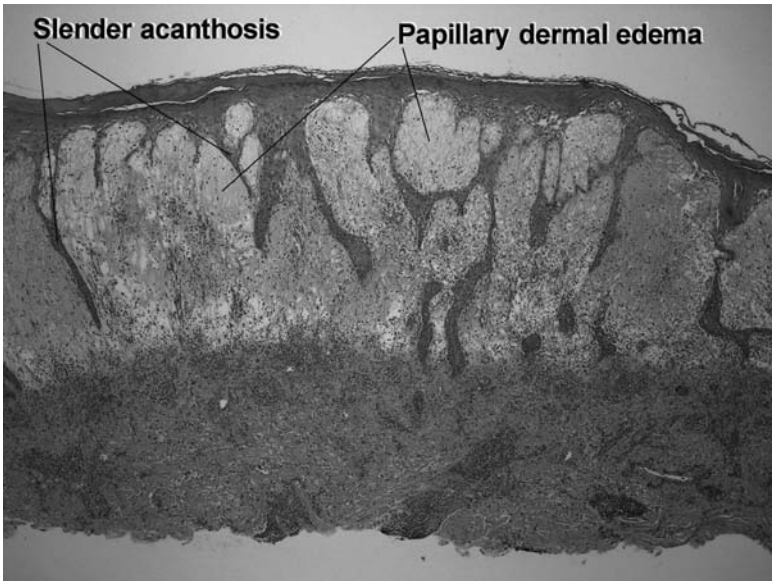
Slender acanthosis
Papillary dermal edema

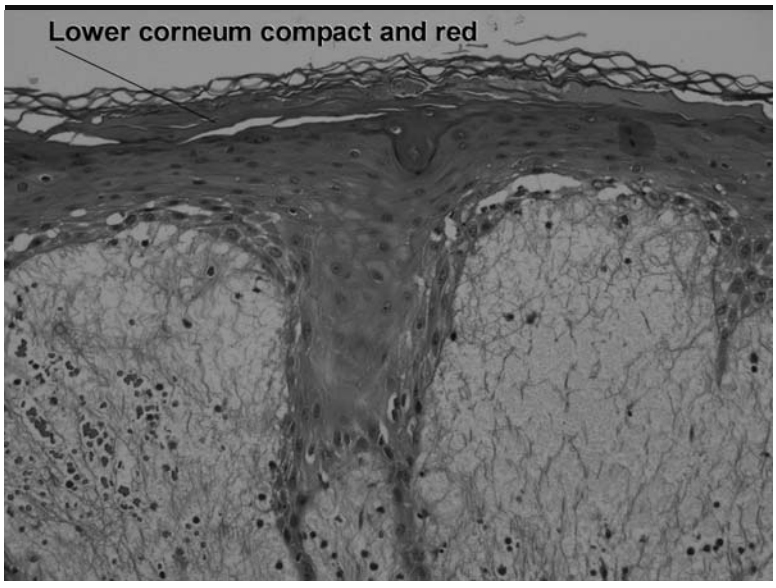
Lower corneum compact and red

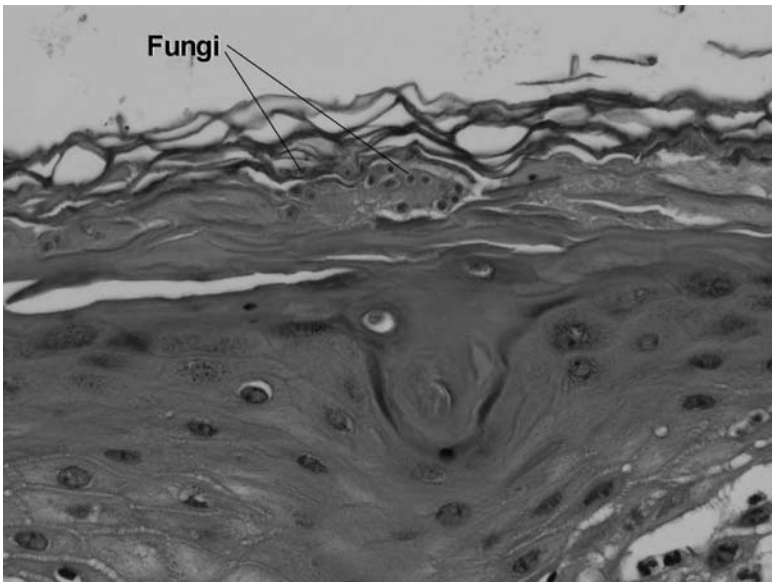
Fungi

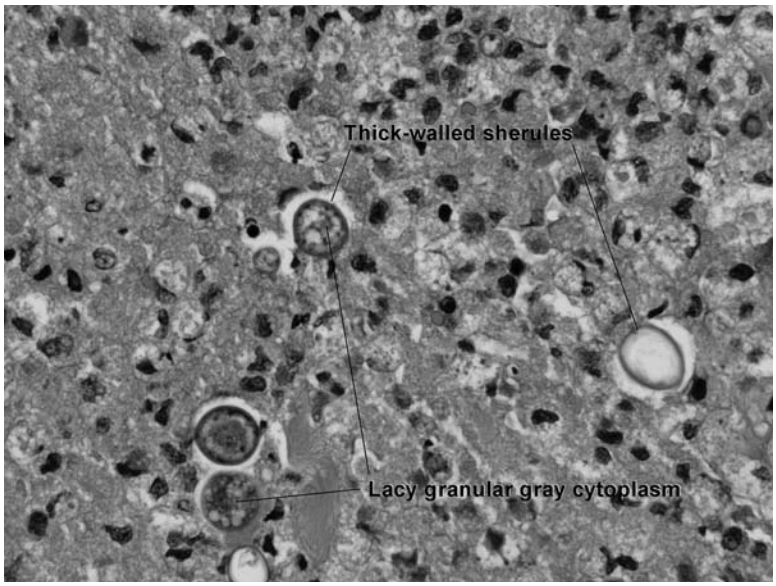
Thick-walled sherules
Lacy granular gray cytoplasm

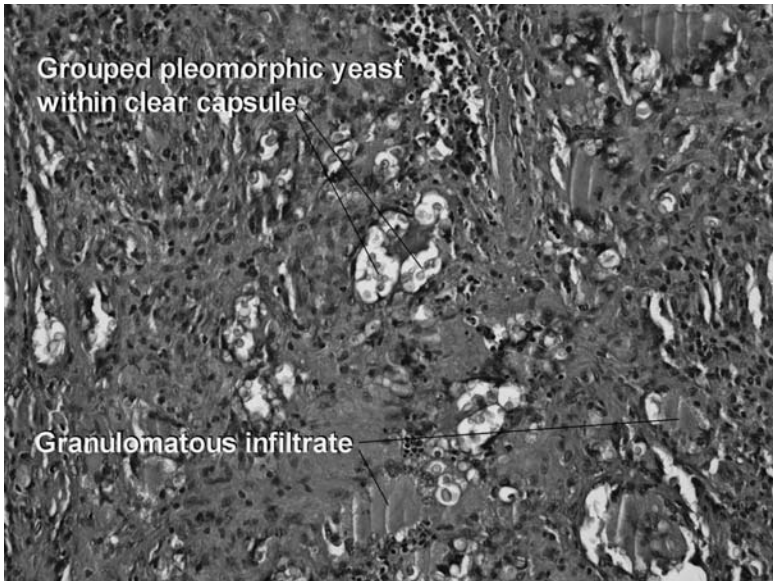
Grouped pleomorphic yeast within clear capsule
Granulomatous infiltrate

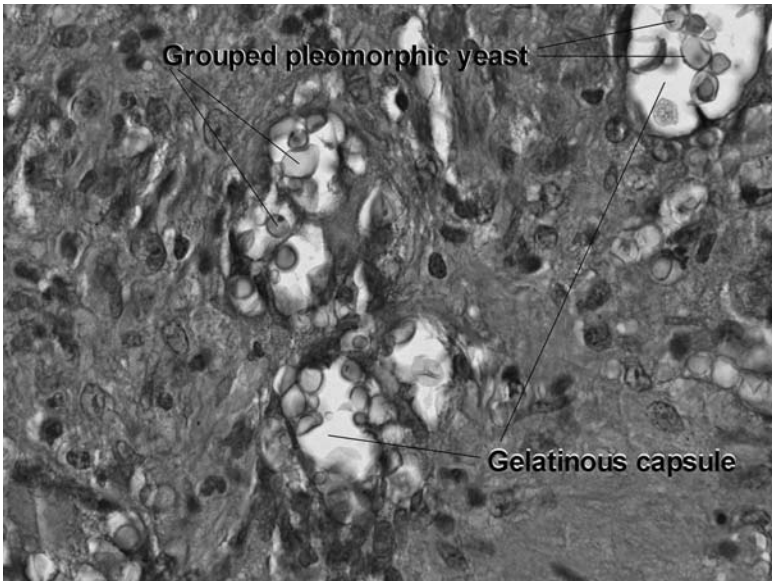
Grouped pleomorphic yeast
Gelatinous capsule

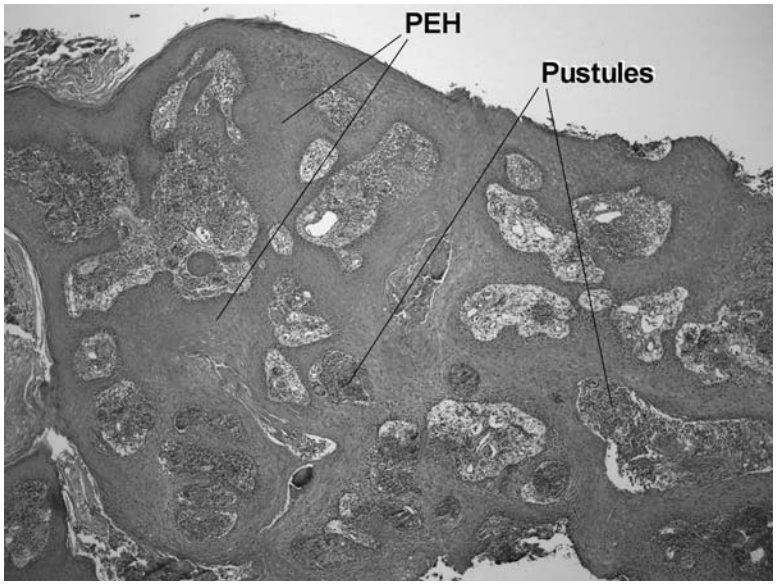
PEH
Pustules

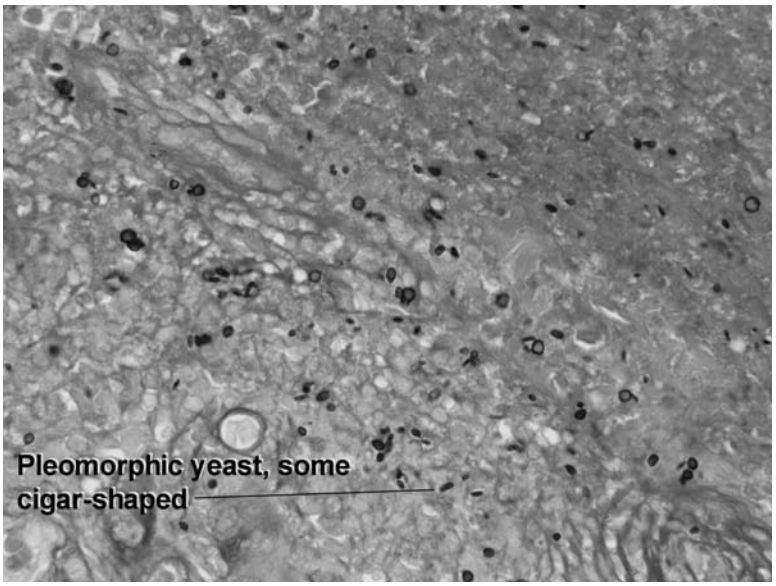
Pleomorphic yeast, some
cigar-shaped

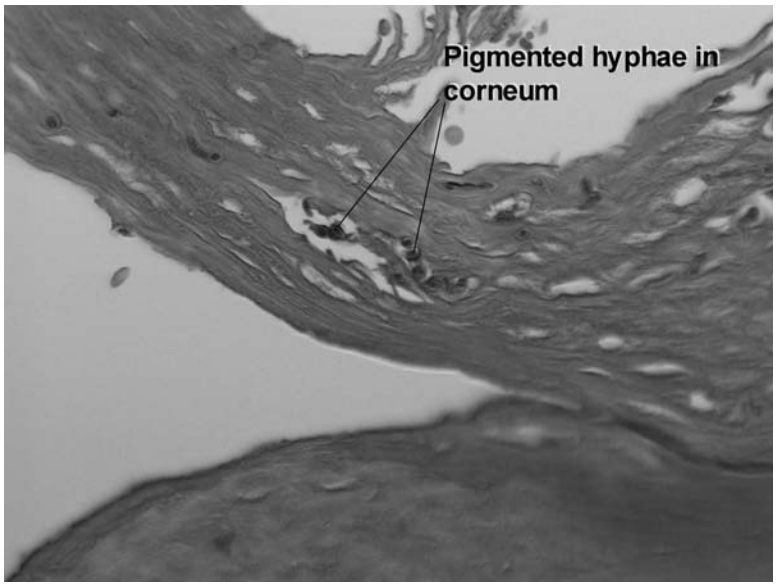
Pigmented hyphae in
corneum

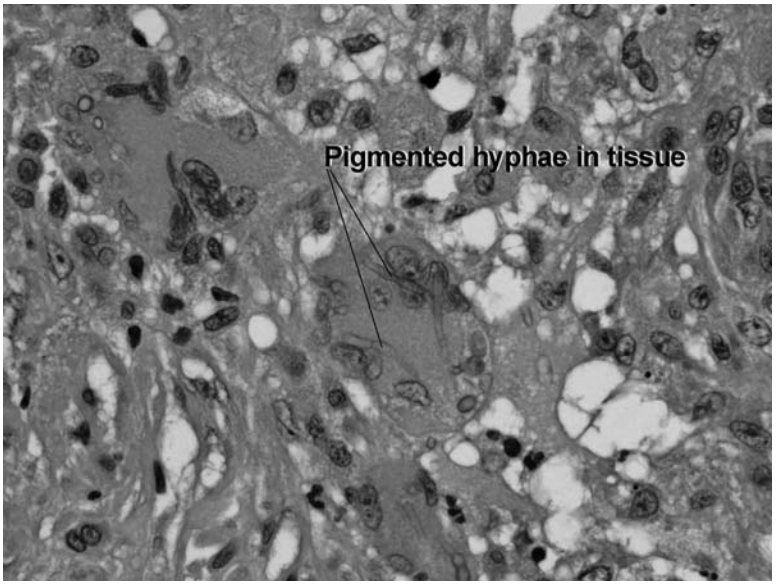
Pigmented hyphae in tissue

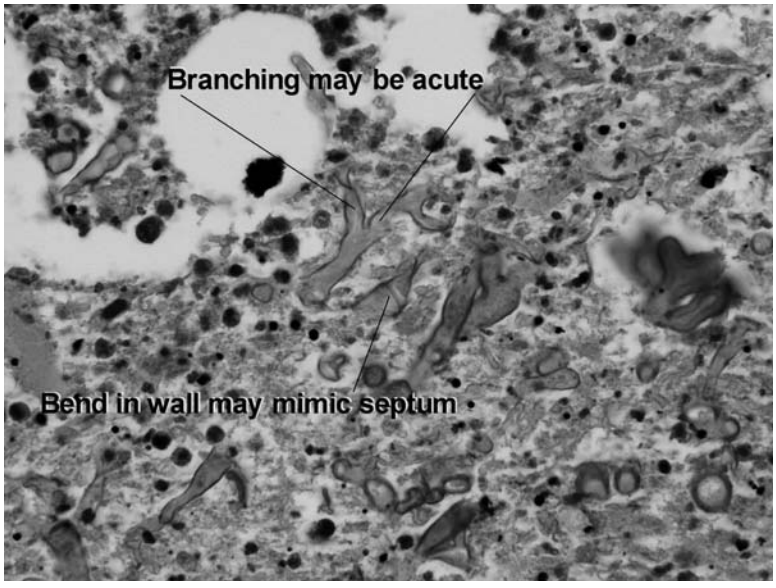
Branching may be acute
Bend in wall may mimic septum

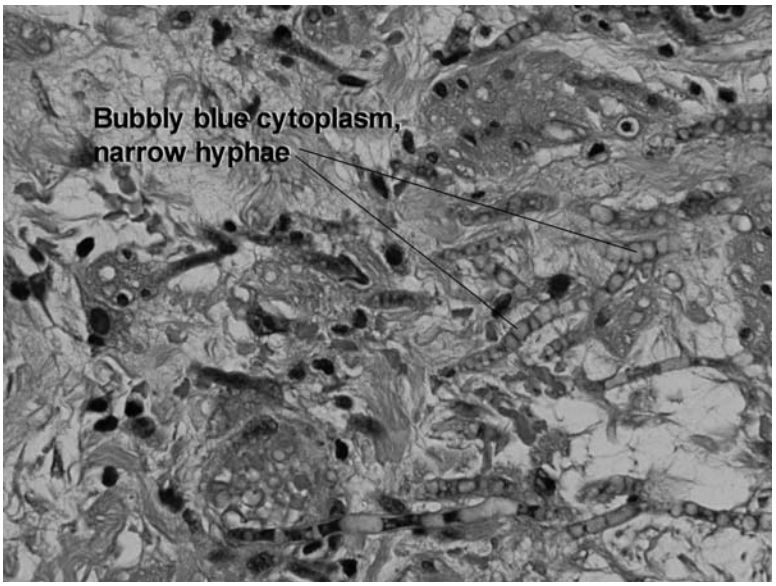
Bubbly blue cytoplasm,
narrow hyphae

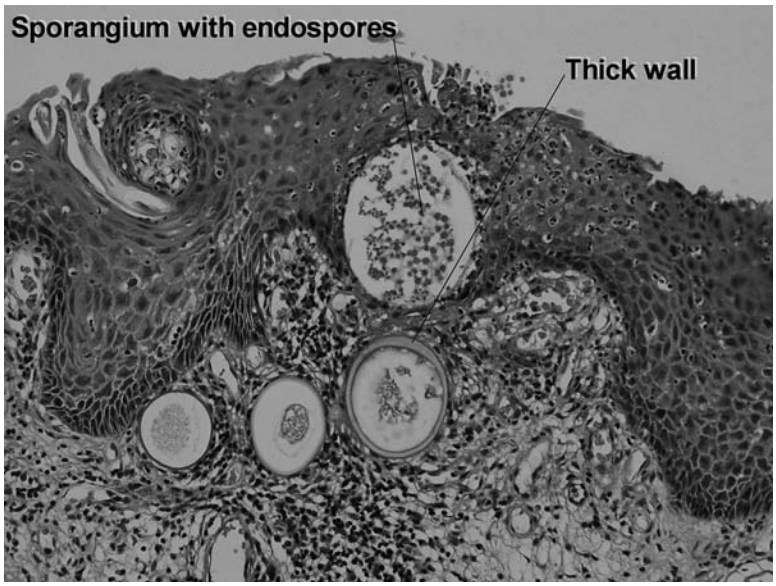
Sporangium with endospores
Thick wall

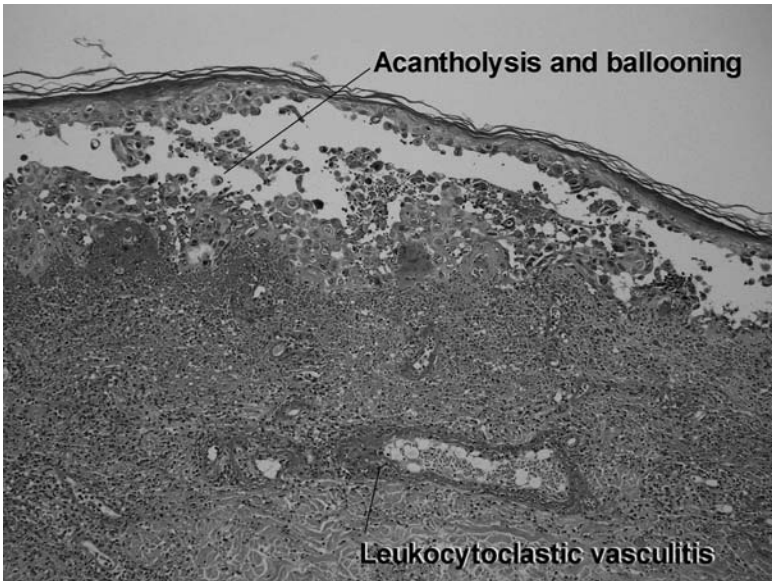
Acantholysis and ballooning
Leukocytoclastic vasculitis

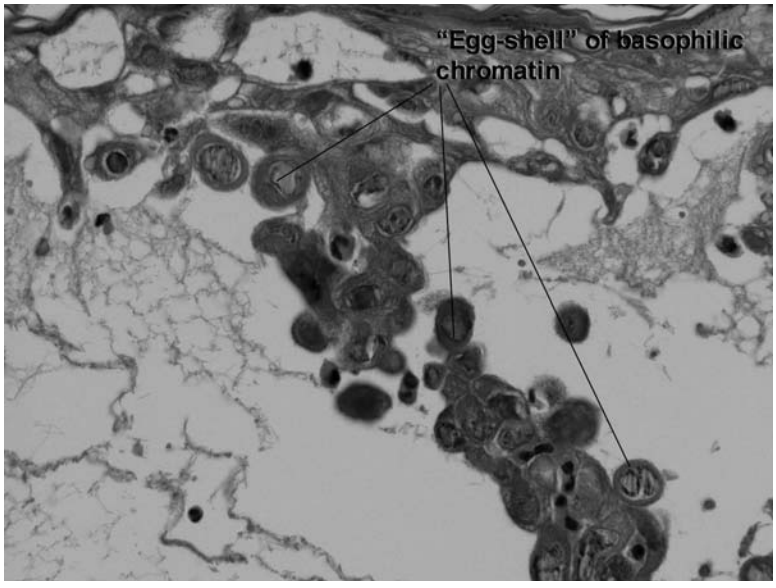
"Egg-shell" of basophilic
chromatin

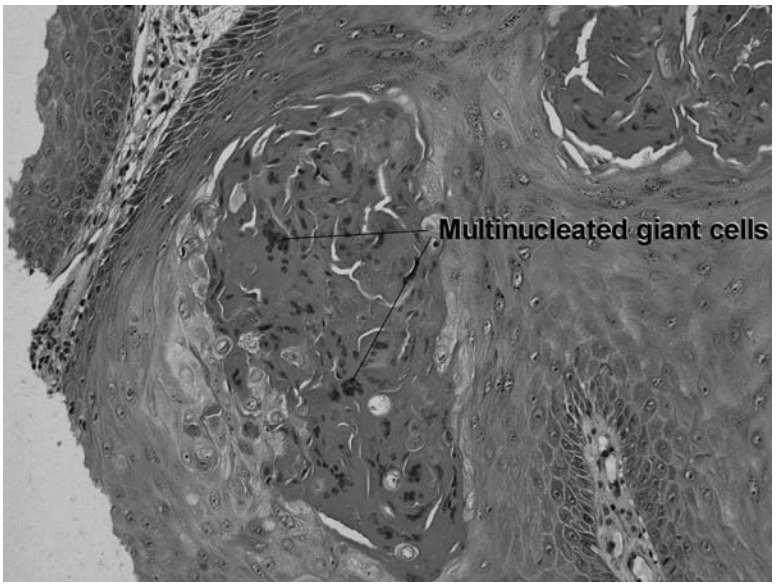
Multinucleated giant cells

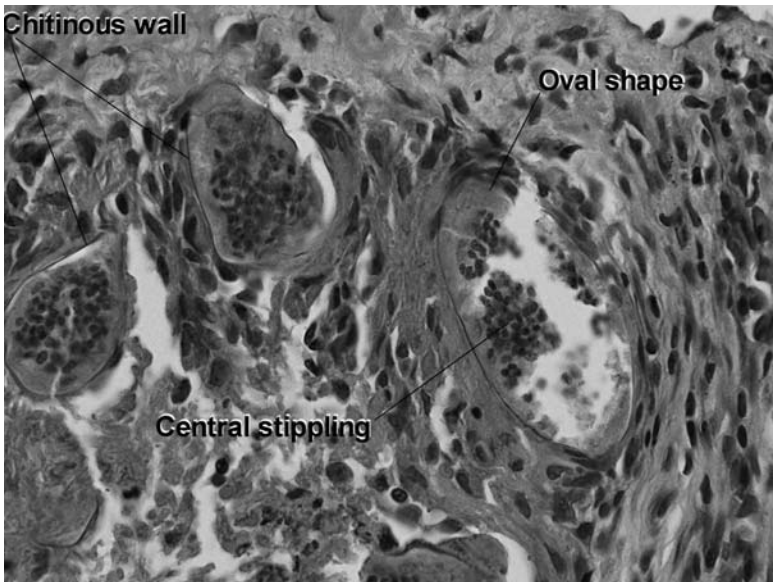
Chitinous wall
Oval shape
Central stippling

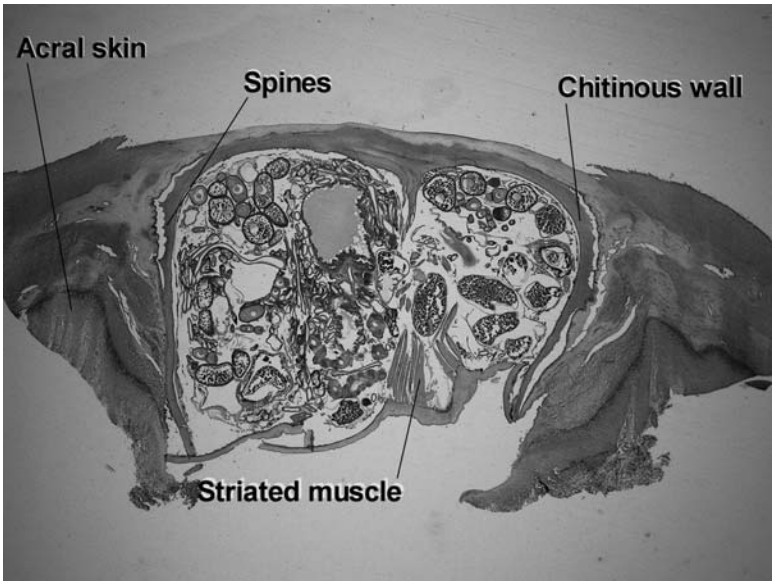
Acral skin
Spines
Chitinous wall
Striated muscle

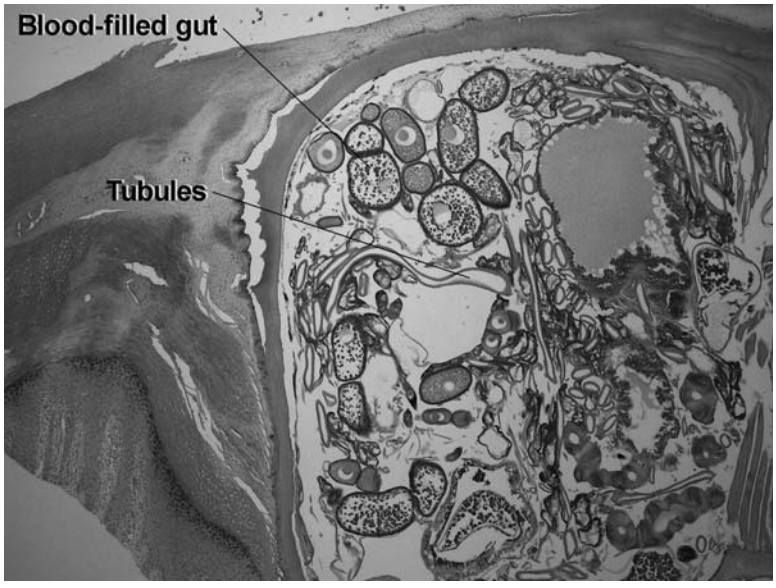
Blood-filled gut
Tubules

Life Threatening Dermatoses

Dirk Elston MD
Professor and Chairman
Department of Dermatology and Dermatologic Surgery
Medical University of South Carolina

Patient #1

- Middle-aged female with seizure disorder
- Rash

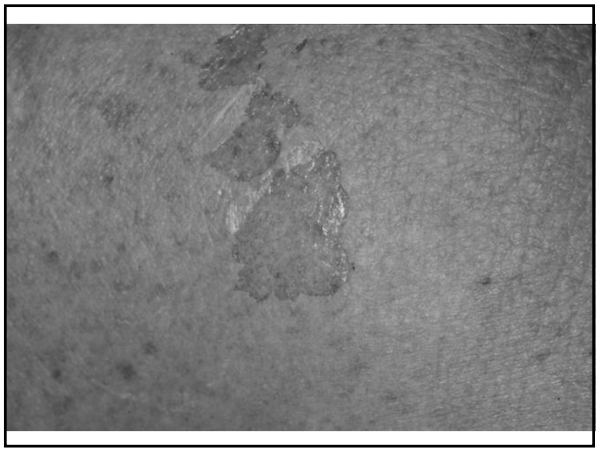

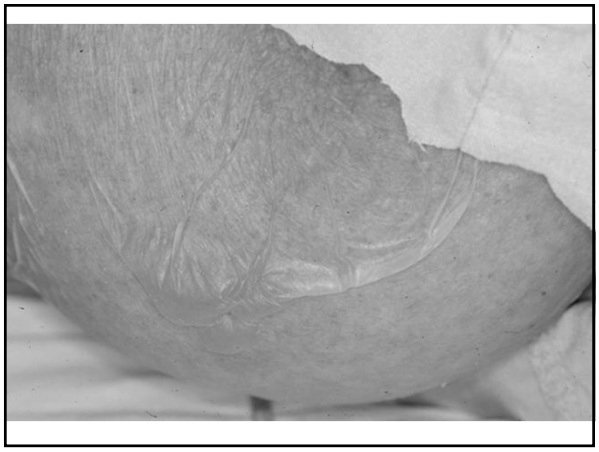

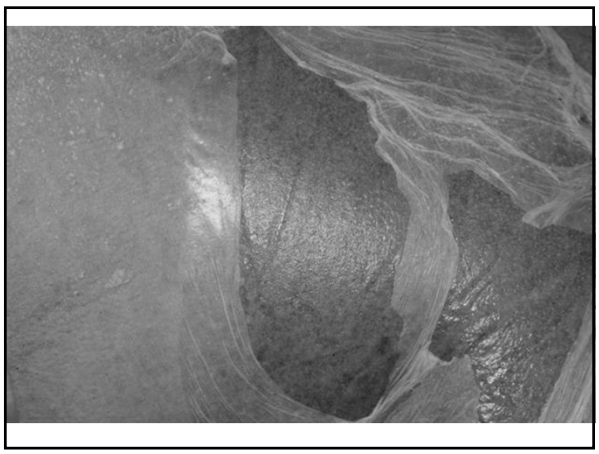

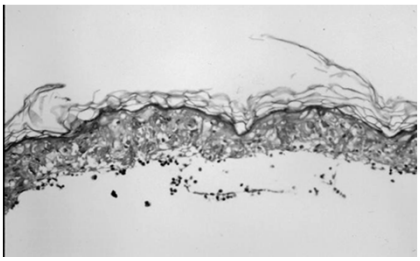

Implicated drugs

- Anticonvulsants
  - –Phenytoin
  - –Phenobarbital
  - –Carbamazepine
  - –Lamotrigine
- NSAIDs

Cross Reactions

- Aromatics (phenytoin)
- Carboxamides (carbamazepine and oxcarbazepine)
- Barbiturates (phenobarbital and primidone)
- Gabapentin
- Tricyclics

- Ann Allergy Asthma Immunol. 2006 Nov;97(5):698-702

Alternative Anticonvulsants

- Valproic acid (Depakote)
- Topiramate (Topamax)
  - Metabolic acidosis, anorexia, cardiac arrhythmias, emotional lability, memory deficits, weight loss, and hypohidrosis, acute myopia, and angle-closure glaucoma
- Felbamate
  - boxed warning liver failure and aplastic anemia
- Levetiracetam (Keppra)
  - Irritability, somnolence, ataxia, headache, psychiatric complaints, anorexia, aggressive behavior

Treatment of TEN

- Burn center
- GCSF (WBC nadir)

- J Burn Care Rehab 1999; 20:406-10
- Int J Dermatol 1996; 35:834-5

Treatment of TEN

- IVIG 3 - 4 gm/kg over 3 or more days
- Data are mixed

Cyclosporin A 3 mg/kg per day

- 11 patients
- Rapid reepithelialization
- Low mortality
- More effective than cyclophosphamide and corticosteroids in historical controls

- J Trauma. 2000 Mar;48(3):473-8.

Thalidomide

- Double-blind, randomized, placebo-controlled study
- 5-day course 400 mg daily
- Study was stopped because of excess mortality in the thalidomide group (10 of 12 patients died, compared with 3 of 10 in the placebo group).
- Lancet 1998;352:1586-1589

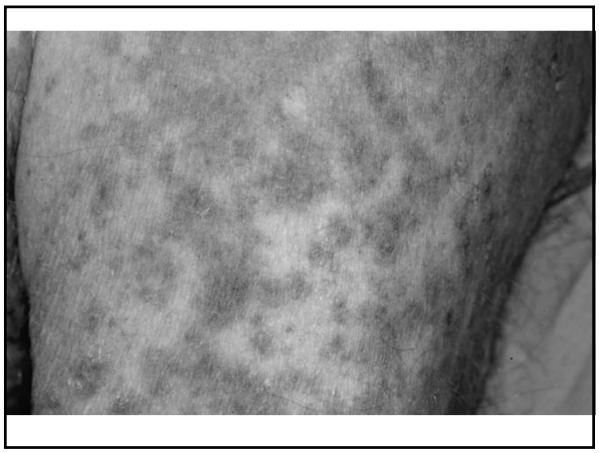

Treatment of SJS

- Supportive care
- Prevention of synechiae
- Cyclosporine eyedrops

Patient #2

- 18 year old with seizure disorder and a rash

Drug Reaction with Eosinophilia and Systemic Symptoms (DRESS)

- Morbilliform rash
- Follicular prominence
- Facial edema
- Malaise
- Lymphadenopathy

Drug Reaction with Eosinophilia and Systemic Symptoms (DRESS)

- Hepatitis/hepatic necrosis (mortality 10%)
- Hypothyroidism

- Treatment: Corticosteroids

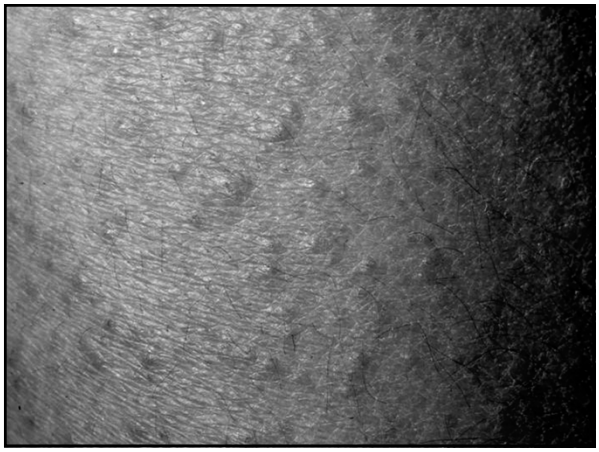

Manifestations Vary by Drug

- **Anticonvulsants**
  - Classic facial edema, eosinophilia, elevated LFTs
- **Allopurinol**
  - Less liver involvement
  - More renal involvement
- **Minocycline**
  - More pulmonary involvement
- **Dapsone**
  - Less eosinophila

Immunol Allergy Clin N Am 29 (2009) 481–501

Patient #3

- 50 y.o. ice cream man
- Motor vehicle accident
- New fungal lesion

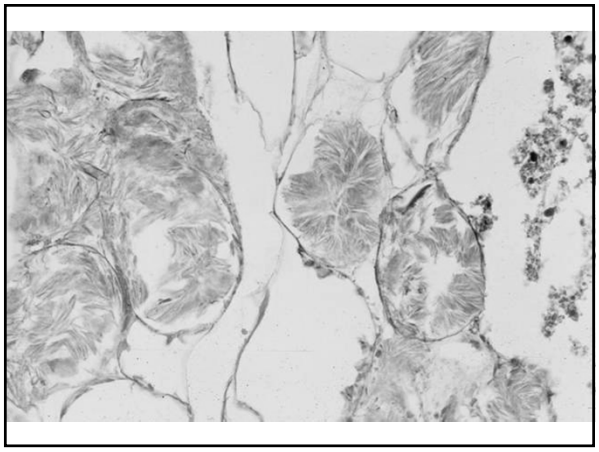

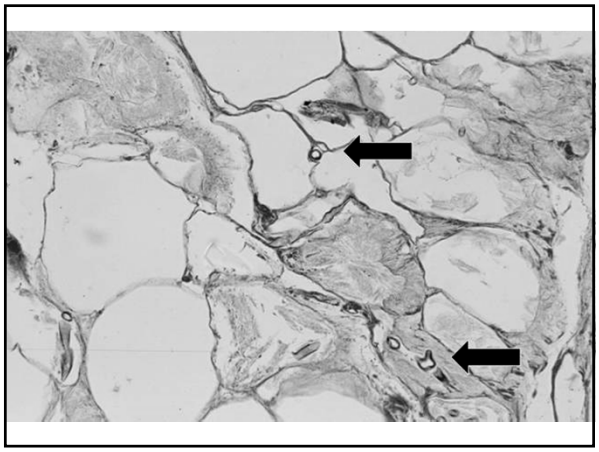

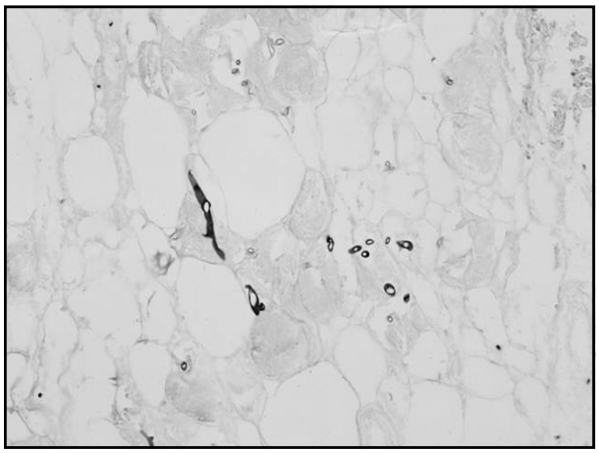

Treatment

- Multiple episodes of debridement until clear margins and no recurrence of necrosis
- Systemic antifungal therapy

Patient #4

- 22 week gestation infant with bedsores
- Ventilator dependent
- Sores noticed on back / buttocks

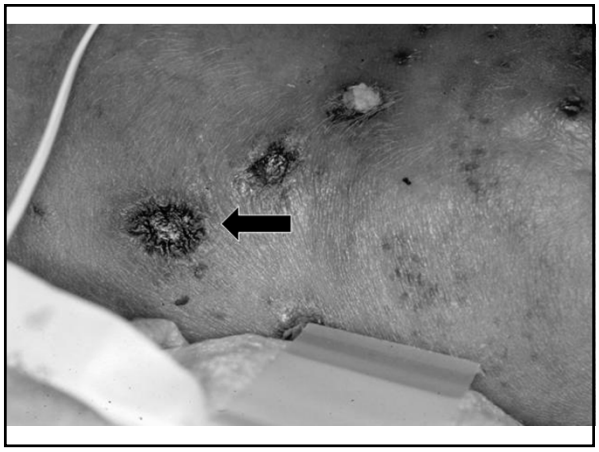

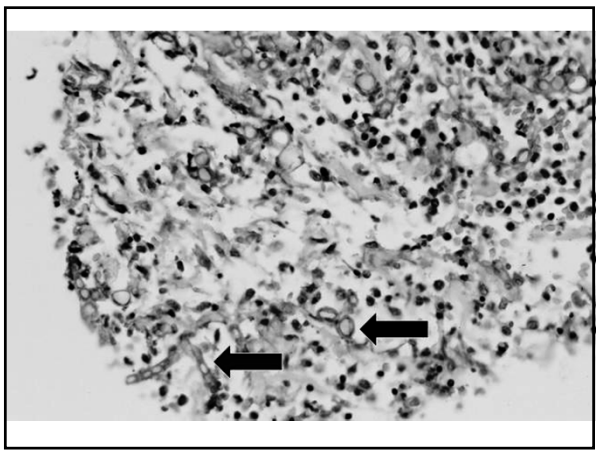

Phaeohyphomycosis

- Superficial (tinea nigra)
- Phaeomycotic cyst
  - Immunocompetent (Phialophora, Exophiala)
- Invasive
  - Immunosuppressed (Bipolaris)

Phaeohyphomycosis

- As a group, highly resistant to amphotericin
- Respond best to massive doses of itraconazole
- Possibly excellent synergism with terbinafine/fluconazole
- Liposome-encapsulted amphotericin B

Patient #5

- Pediatrics resident with a rash

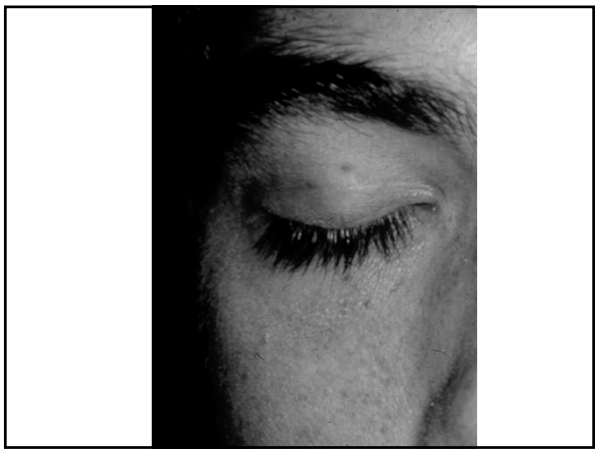

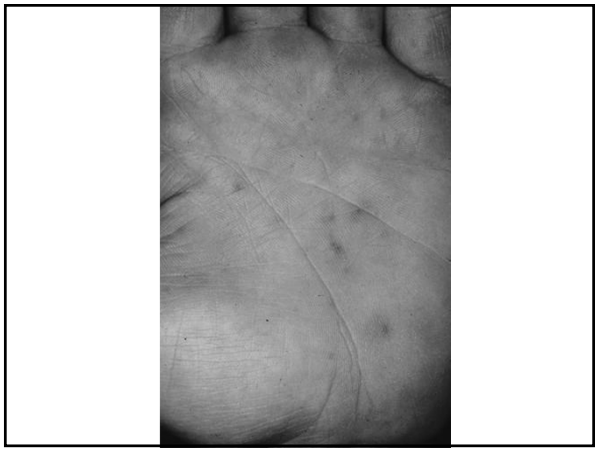

Diagnosis:

- Meningicoccemia

Lessons learned

- Angular infarcts, red rim, gun-metal gray interior
- Expect acute adrenal crisis

Patient #7

- Orange juice burns mouth

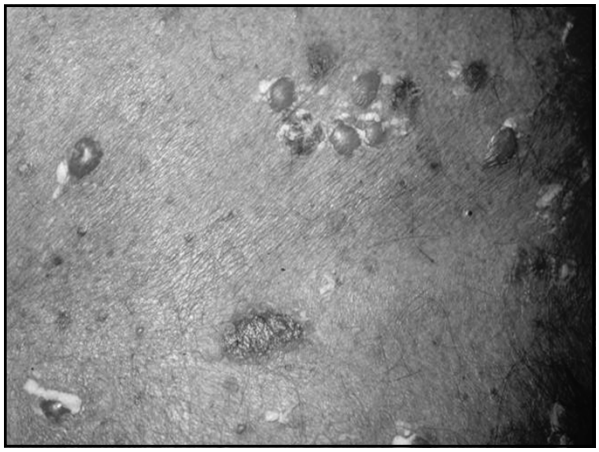

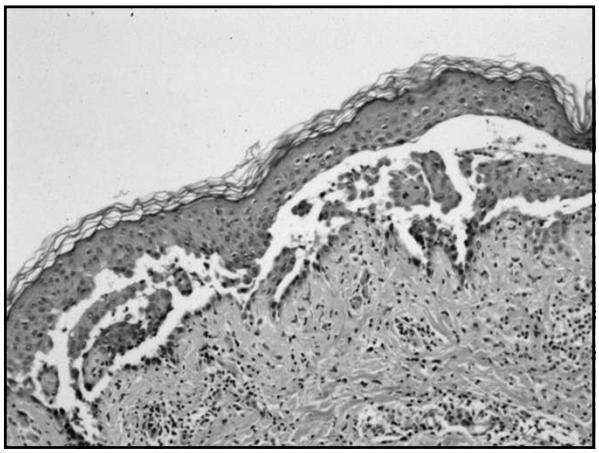

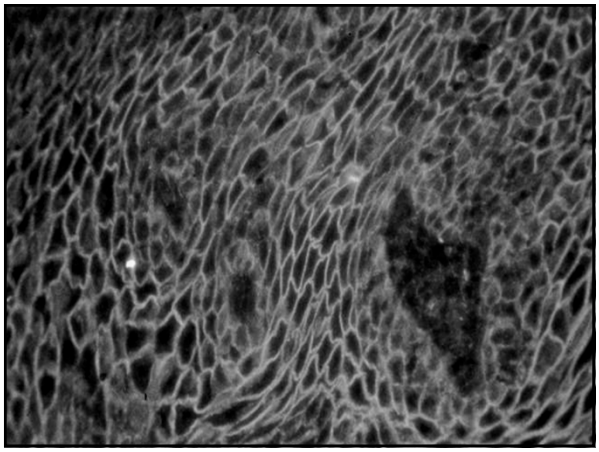

Diagnosis:

- Pemphigus vulgaris

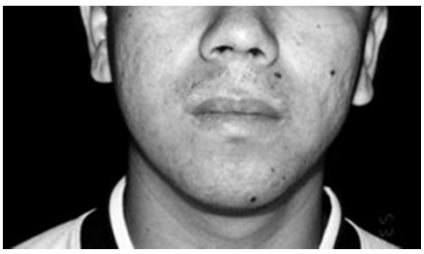

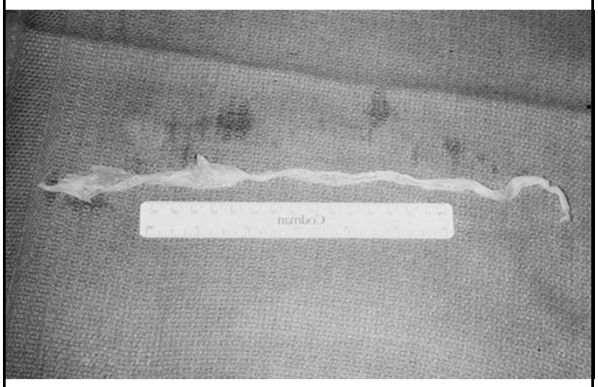

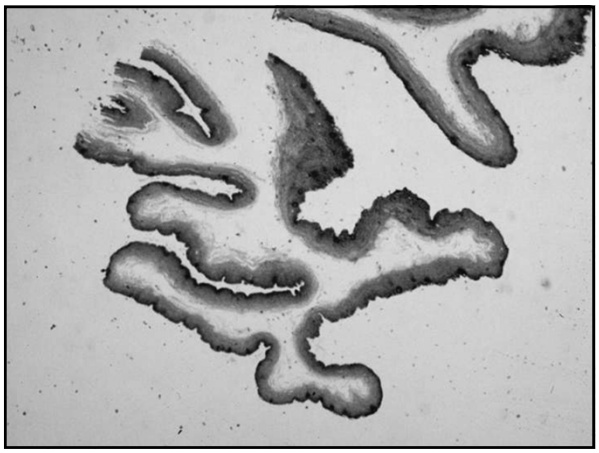

Lessons learned:

- Esophagitis dessicans often appears when pemphigus appears well controlled
- NG tube
- Proton-pump inhibitor

Lessons learned

- Rituximab can be life-saving
- Pulse cyclophosphamide rather than daily dose whenever possible if cytotoxics are used

Patient #8

- BMT patient with rash

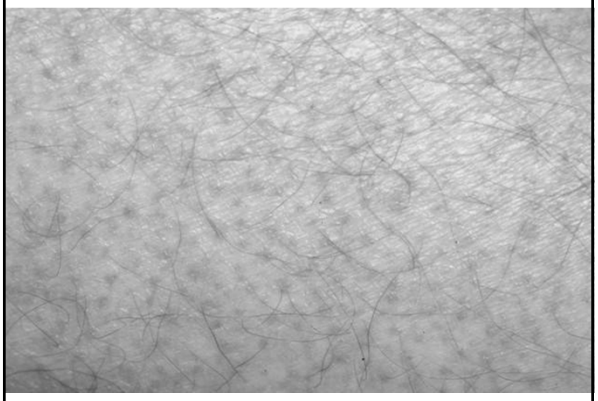



Diagnosis

- Graft vs Host Disease (GVHD)

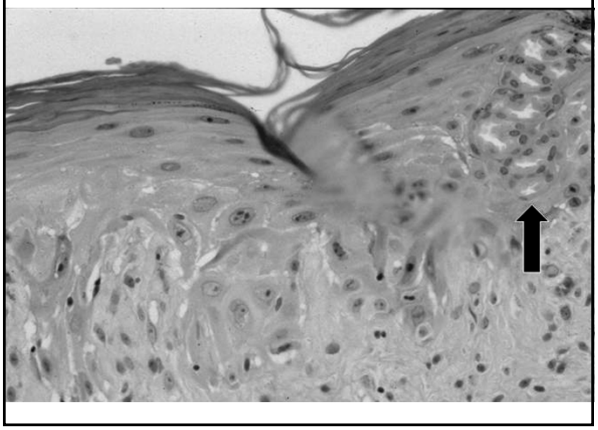



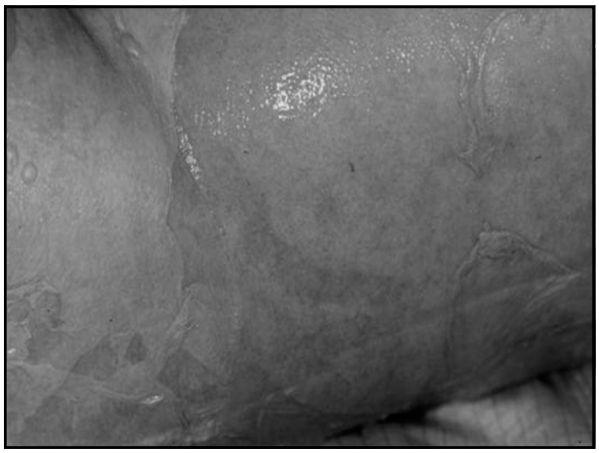

Diagnosis

- Grade 4 GVHD
- Died of pneumonitis

Lessons learned

- Acute GVH can progress rapidly
- Severe skin disease often correlates with severe visceral disease
- Skin DX allows early aggressive treatment with steroids, cyclosporine, etc.

Patient #10

- Wedding in two weeks
- Doesn't like scars and dark moles

Diagnosis

- Addison’s disease

Lessons learned

- If you see darkening scars, darkening nevi, tan, mucosal pigment, nail streaks . . .
- Get ACTH or endocrine evaluation
  - K: 5.2
  - ACTH: 1605 pg/ml (5 - 18)

Patient #11

- 52 y.o. female with end-stage renal disease
- s/p bowel necrosis, dehiscence, pseudomonas sepsis
- Rash

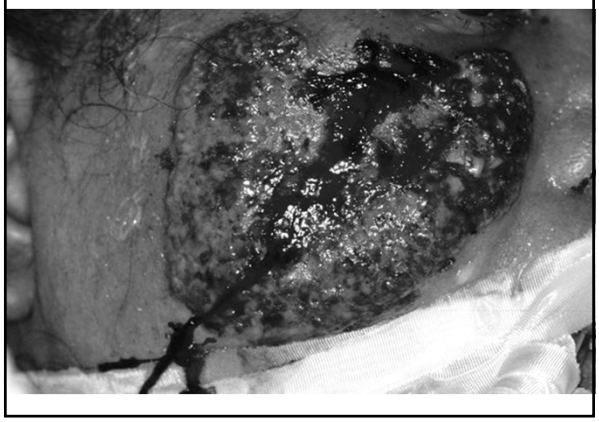

Rapid diagnosis

- 4 hour tissue processing
- tissue homogenate
  calcafluor white
  gram stain
  rhodamine-auramine
  culture

Spongiform pustules

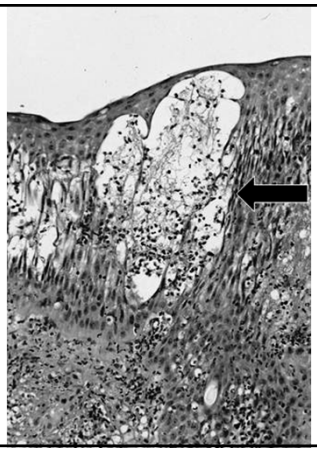

Suppurative folliculitis

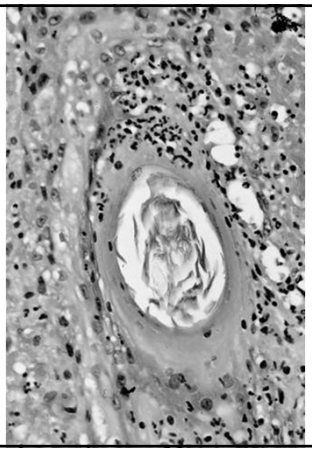

Leukocytoclastic vasculitis

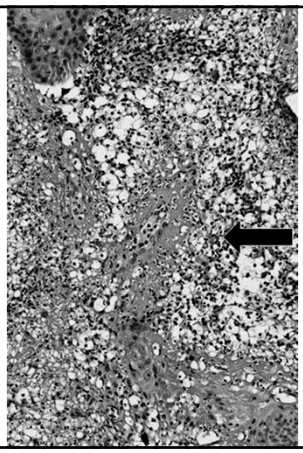

Suppurative dermatitis / folliculitis / vasculitis

- Iododerma (from imaging studies)
  - Patients die of refractory pneumonitis

What to do next:

- Call the surgeons:
  Advise high dose systemic steroids for a condition they have never heard of
- Call the dialysis team:
  Advise heroic dialysis in a patient with a normal BUN/Cr

5 days after initiation of corticosteroid therapy

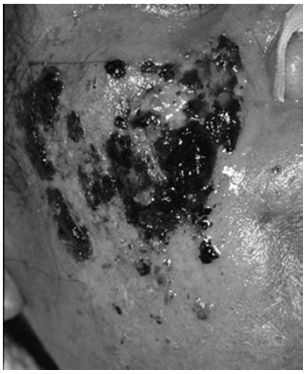

Lessons Learned

- Dialysis patients have elevated baseline iodine
- Levels increase markedly with IV contrast
- Dialysis lowers iodine slowly

Patient #12

- 18 year old WM
- Acutely ill, febrile, coma, renal failure, myocardial infarction
- Blood culture broth: Acridine orange single organism
- Skin lesions

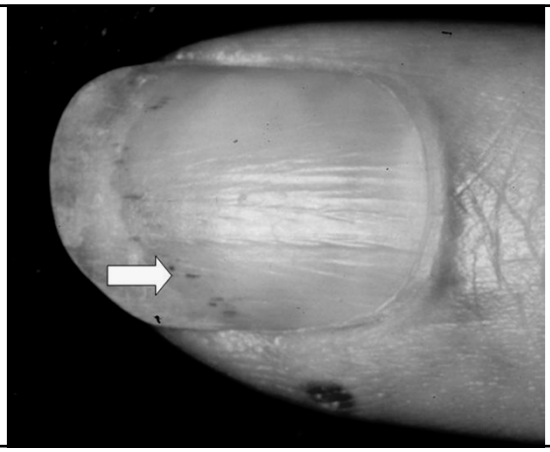

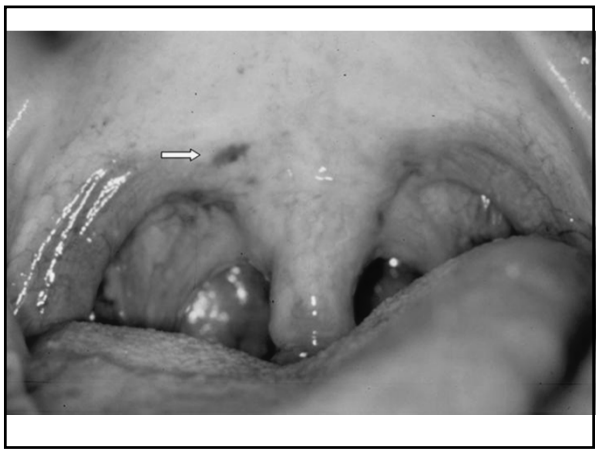

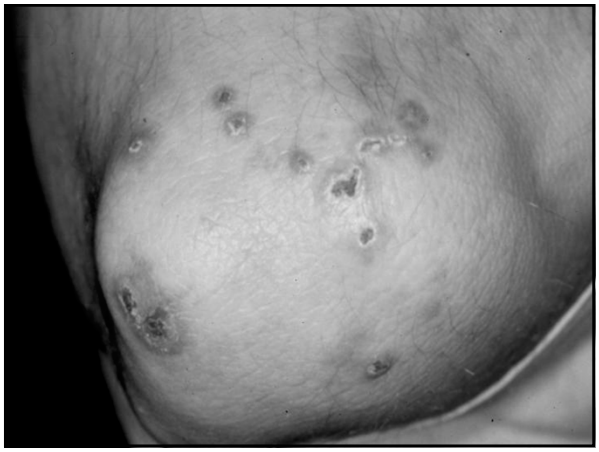

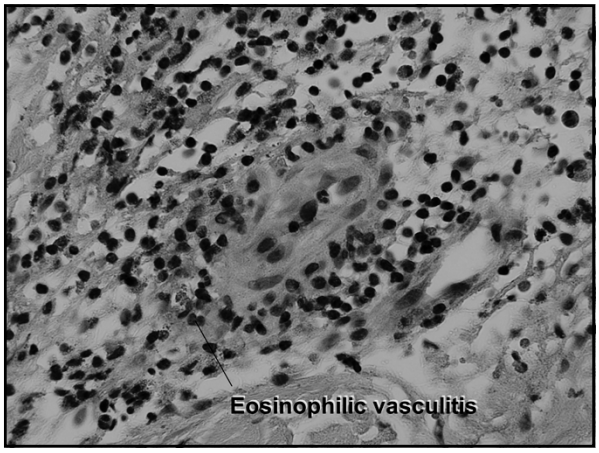
Eosinophilic vasculitis



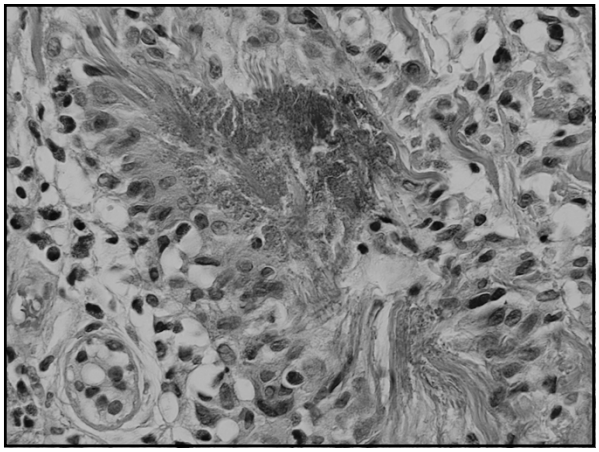

Churg-Strauss Syndrome

- Triphasic
  - –Allergic rhinitis/asthma
  - –Eosinophilia/tissue infiltration
  - –Vasculitis

Churg-Strauss Syndrome

- Cardiac
  - Small vessel vasculitis, pericarditis, myocardial thickening
- Lung
  - Asthma, infiltrates
- Sinus
  - Common

Wegener's Granulomatosis

Wegener's Granulomatosis

- Upper airway and renal
- c-ANCA
- Necrotizing vasculitis
- Palisading granulomas with giant cells and PMN's

Severe Vasculitis

- Treatment:
  - Prednisone
  - Sulfa (Wegener's)
  - Pulse cyclophosphamide
  - Daily oral cytoxan (AM with hydration)

Patient #6

- Comatose, febrile patient
- Recent cardiac catheterization
- New murmur

- Echocardiogram and repeated blood cultures negative

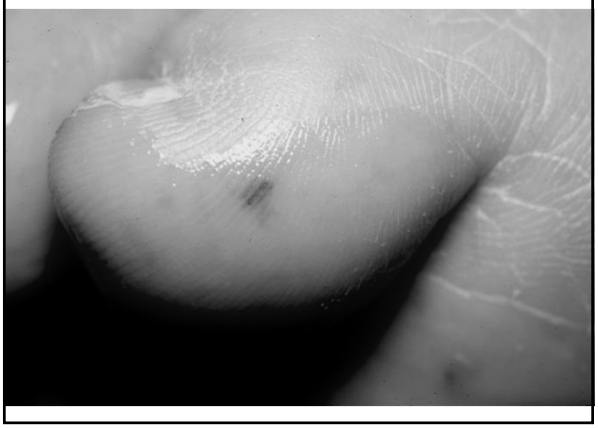

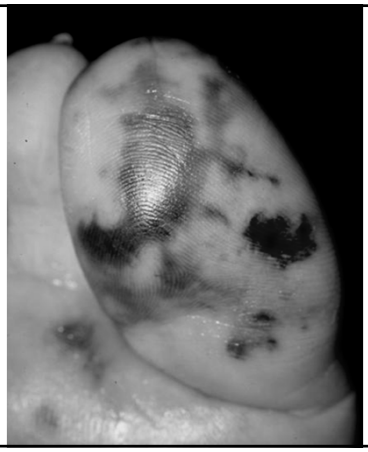

Janeway lesion

- Osler's nodes:
  - Tender pink papules
  - SBE
- Janeway:
  - Non-tender, angular infarct
  - ABE

- Transesophageal echo:
  - vegetation

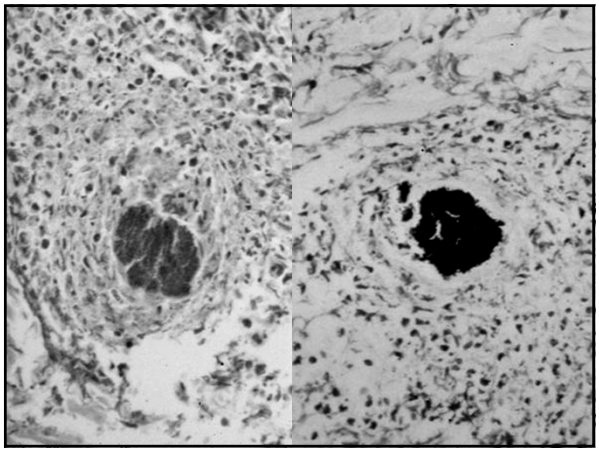

Lessons learned

- Lab tests and echocardiograms can lie
- Dermatology is truth